



Sonographic Assessment of Normal Fetal Cerebral Lateral Ventricular Diameter at Different Gestational Ages

**Benjamin Effiong Udoh^{1*}, Ogbu Sylvanus², Wilson Imo Uduak¹
and Ulu Okoro Ulu³**

¹*Department of Radiography and Radiological Science, Faculty of Allied Medical Sciences, University of Calabar, Calabar, Nigeria.*

²*Department of Radiography and Radiological Science, Faculty of Health Sciences and Technology, University of Nigeria, Nigeria.*

³*Department of Radiology, Jos University Teaching Hospital, Jos, Nigeria.*

Authors' contributions

This work was carried out in collaboration between all authors. All authors read and approved the final manuscript.

Article Information

DOI: 10.9734/JAMMR/2019/v30i130156

Editor(s):

(1) Dr. Thomas I. Nathaniel, University of South Carolina, School of Medicine-Greenville, Greenville, USA.

(2) Dr. Chan-Min Liu, School of Life Science, Xuzhou Normal University, Xuzhou City, China.

Reviewers:

(1) Bukunmi M. Idowu, Nigeria.

(2) Katherine Athayde Teixeira de Carvalho, Pequeno Príncipe College, Brazil.

(3) Juan Gabriel Avina-Cervantes, University of Guanajuato, Campus Irapuato-Salamanca, Mexico.

Complete Peer review History: <http://www.sdiarticle3.com/review-history/34770>

Received 10 January 2017

Accepted 20 January 2018

Published 27 June 2019

Original Research Article

ABSTRACT

Abnormal dilatation of ventricles has been shown to be the most common abnormality of the brain & fetus in most of the geographical zones, but the normal dimension of the fetal lateral ventricle in south-south geopolitical zones of Nigeria has not been evaluated.

The aim of this study was to determine the normal feto-lateral ventricular diameter using ultrasound at different gestational ages.

Measurement of the fetal-lateral ventricular diameter was obtained from 685 fetuses of pregnant mothers that met the inclusion criteria during routine ultrasound scan in Calabar metropolis. Measurement of the ventricular diameter was taken at the level of the atria, measured according to Australian society for ultrasound in medicine guidelines.

*Corresponding author: E-mail: ben123trio@yahoo.com;

The result shows that the mean lateral ventricular diameter of fetuses in the studied region is 6.62 ± 2.51 mm with a range of 4.12-9.54 mm. The lateral ventricular diameter and the fetal head circumferences, as well as the gestational age, do not show any significant correlation throughout gestation.

Conclusion: Fetuses in Calabar Metropolis have a lateral ventricular diameter that ranges from 4.12 - 9.54 mm. Ventricular diameter above this normal range in this region and could be considered as an abnormal and may demand further investigations.

Keywords: Anatomy; cerebral; sonography; lateral ventricle; head circumference.

1. INTRODUCTION

The fetal cerebral ventricular system consists of two lateral ventricles and the midline third and fourth ventricles connected by the midline cerebral aqueduct [1]. The lateral ventricles are the first and the second ventricles and are the largest counters in the ventricular system and occupy a large area of the fetal cerebral hemispheres. Each lateral ventricle opens into the third ventricle through the interventricular foramen. The third ventricle is a slit-like cavity between the right and left halves of the diencephalon which is continuous posteroinferiorly with the cerebral aqueduct. The fourth ventricle in the posterior part of the pons and medulla extends inferior- posteriorly, which is continuous with the central canal in the spinal cord.

Increase in the fetal skull dimension had been suggested to be due to the alterations of the ventricular system diameters [2], that is, the distance of each ventricle from one wall to another. Increase in size of the anterior horn of the lateral ventricle; initially take place in its anteroposterior portion in most cases of ventricular dilatation. Therefore at this stage of ventricular dilatation, the Ventricular Hemisphere Ratio (VHR) may still be normal and not very efficient for early diagnosis of ventricular dilatation [3].

Fetal cerebral ventriculomegaly and Hydrocephalus has been shown to be the known causes of the fetal ventricular system dilatation [4]. This also leads to the alteration in the fetal ventricular diameters. The diagnosis of ventriculomegaly and hydrocephalus are important for several reasons: the abnormal dilatation & may impact adversely on the normal development of the fetal brain; the dilatation may be part of or result of other neural axis abnormalities or the dilatation may be part or signal the presence of other syndromic or non neural axis abnormalities [5].

The widely used definition of fetal ventriculomegaly is a transtrigone measurement of ≥ 10 mm at any stage of pregnancy and fetal ventriculomegaly is one of the most common findings on second-trimester obstetrical ultrasound examination [6]. Ventriculomegaly can be caused by a variety of disorders which results in neurological, motor and/or cognitive disorders impairment [6]. Many cases are associated with other abnormal findings, but in some fetuses, ventriculomegaly is the only abnormality [7].

Fetal ventriculomegaly can also result from a number of underlying pathological mechanisms which include in-utero fetal system structures anomalies and inutero fetal infections [8]. The central nervous system structures anomalies include Dandy-Walker continuum, Chiari II malformation, aqueductal stenosis and agenesis of the corpus callosum. Inutero fetal infection(s) include inutero toxoplasmosis infection and inutero cytomegalovirus (CMV) infection [8].

Ventriculomegaly is usually described as being mild, moderate and severe based on sonographic measurement of the size of the lateral ventricles [9].

Hydrocephalus is the correct term for pathologic dilatation of the brains ventricular system from increased pressure, usually due to obstruction [7]. It is defined as an abnormal increase in diameter of the lateral ventricles unrelated to dysgenesis or cerebral atrophy which is often the presenting sonographic sign of a CNS abnormality. Hydrocephalus can be caused by obstruction to the flow of cerebrospinal fluid (CSF) anywhere between the site of formation and absorption, decreased re-absorption of CSF or an excessive rate of CSF formation.

Hydrocephalus occurs in some percentages of live births in different epidemiological surveys. For example 3000 - 6000 new cases of hydrocephalus was recorded in Ethiopia [10]. The prenatal diagnosis relies on the demonstration of

enlarged ventricles and/or the effects of increased cerebrospinal fluid CSF pressure.

2. METHODOLOGY

The pregnant mothers that met the inclusion criteria were well received at the reception. After brief instructions to the pregnant mothers; they were taken into the ultrasound room, and were asked to lie supine on the ultrasound couch.

Sufficient ultrasound gel was applied to the abdomen. Scanning was done at different planes until a good ovoid shape of the fetal skull was achieved. Measurement of the ventricular diameter was taken at the level of the atria, measured according to Australian society for ultrasound in medicine guidelines. Cursors were placed from the anterior wall to the posterior wall and the diameter read off electronically. Other parameters of the fetal skull such as Biparietal diameter (BPD), gestational age (GA) and Head Circumference were also determined.

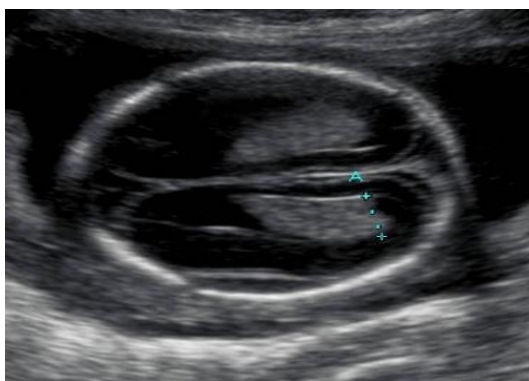


Fig. 1. Sonogram of a second trimester normal lateral ventricular diameter. The caliper indicates the boundary of measurement of fetal lateral ventricular diameter

3. DATA ANALYSIS

The lateral ventricular diameter was grouped according to gestational age, sex, and head circumference. Descriptive statistics were used to find the mean, standard deviation and range while inferential statistics were used to determine the correlation of the variable with bio-data. $P < 0.05$ was taken as the level of statistical significance. The data was analyzed using statistical package for social science version 16.0.

4. RESULTS

Sonographic measurements of the normal lateral ventricular diameter were obtained in 685 fetuses between 20 and 40 weeks of gestation. The mean of the lateral ventricular diameter of this study was 6.62 ± 2.51 mm. It ranged from 4.12 - 9.54 mm. The lateral ventricular diameter did not show any significant correlation with gender and the fetal head circumference throughout gestation. Fetal ventricular diameter did not linearly increase with gestational age.

5. DISCUSSION

Ventriculomegaly affects 1-2 in 1000 birth (Pilu et al. 2000) [11] and the prognosis of this abnormality is well documented in literature but mild ventriculomegaly (MVM) has been a matter of discourse among researchers.

The mean fetal lateral ventricular diameter in this study was 6.62 ± 2.51 mm. It ranged from 4.12 - 9.54 mm. The result of this study also demonstrates that there is no correlation between lateral ventricular diameter with gestational age (GA) and head circumference. The findings of Farrell et al., (1994) [12] and Patel et al., (1995) [13] are similar to the findings of this study.

Table 1. Distribution of Ventricular Diameter (VD) according to Gestational Age (GA)

| Gestational age | Number of fetuses | Mean VD | Standard deviation |
|-----------------|-------------------|-------------|--------------------|
| 20-21 | 61 | 5.86 | 2.31 |
| 22-23 | 50 | 5.72 | 2.42 |
| 24-25 | 75 | 5.92 | 2.33 |
| 26-27 | 59 | 7.01 | 2.25 |
| 28-29 | 96 | 6.33 | 2.51 |
| 30-31 | 86 | 6.23 | 2.41 |
| 32-33 | 93 | 5.89 | 2.22 |
| 34-35 | 78 | 5.23 | 2.41 |
| 36-40 | 87 | 7.55 | 2.81 |
| N = 685 | | Mean = 6.62 | SD = 2.51 |

Correlation of the Normal Fetal Lateral Ventricular Diameter with Gestational Age, gender, and Head Circumference

| Bio-data | Gestational age | Sex | Head circumference |
|-------------------------------------|-----------------|------|--------------------|
| Pearson Correlation Coefficient (r) | 0.03 | 0.01 | 0.06 |
| P value | 0.53 | 0.72 | 0.31 |
| N | 163 | | |

Other studies presented results higher than what was obtained in this study. Cardoza et al., (1995) [14] retrospectively evaluated 100 healthy fetuses and found a mean fetal lateral ventricular diameter of 7.6± 0.6 mm. Some other studies [15,16] reported 7.7 ± 0.7 mm as mean lateral ventricular diameter.

The lateral ventricular atrium diameter had been said to remain less than 10 mm in diameter throughout gestation [17]. Enlargement of the ventricles may occur for a number of reasons, such as loss of brain volume (perhaps due to infection or infarction), or impaired outflow or absorption of cerebrospinal fluid [1].

Several studies supported the use of 10mm as the upper limit for the lateral ventricular diameter and the use of either 2 or 4 standard diameters above the mean [6]. Pretorius et al., (1995) [18] and Hilbert et al., (1995) [19] rather suggest 11mm and 12 mm (respectively) to be the upper normal limit. Yet some other studies Siedler and Filly (1987) [20] gave lower limits of 4 mm and 8mm as a normal fetal ventricular measurement.

Alteration in the lateral ventricular diameter above the upper limit of 10 mm is agreed by many researchers to be diagnostic of ventriculomegaly but many fetuses with isolated mild ventriculomegaly, i.e. ventricular enlargement greater than 10 mm, turned out to have no abnormalities on neonatal assessment [11]. Ventriculomegaly is usually described as being mild, moderate or severe based on the measured size of the lateral ventricles.

Our studies show that lateral ventricular diameter does not increase with gestational age. This is a plausible finding because if the lateral ventricle dramatically increases in diameter throughout gestation, the diagnosis of hydrocephalus might be difficult [5]. Hydrocephalus is usually diagnosed in utero by the measurement of the fetal lateral ventricular diameter. Head circumference, which linearly increases with gestational age, had no correlation with fetal lateral ventricular diameter despite the fact that the lateral ventricles occupy a large area of the fetal cerebral hemispheres. This again, indicates

that the diameter of the lateral ventricle does not necessarily depend on the circumference of the head.

6. CONCLUSION

The present study shows that the normal ventricular diameter of fetuses in Calabar Metropolis is ranged from 4.12 - 9.54 mm. The mean of the value was 6.62 ± 2.51 mm. Ventricular diameter above this normal range in this region could be considered abnormal and may demand further investigations.

CONSENT

As per international standard or university standard written patient consent has been collected and preserved by the authors.

ETHICAL APPROVAL

As per international standard or university standard written ethical permission has been collected and preserved by the authors.

COMPETING INTERESTS

Authors have declared that no competing interests exist.

REFERENCES

1. Cardoza JD, Goldstein RB, Filly RA. Exclusion of fetal ventriculomegaly with a single measurement: The width of the lateral ventricular atrium. *Radiology*. 1988;169:711-714.
2. Breeze AC, Alexander PM, Murdoch EM, Missfelder-Lobos HH, Hackett GA, Lees CC. Obstetric and neonatal outcomes in severe fetal ventriculomegaly. *Prenat Diagn*. 2007;27(2):124-9.
3. Gaglioti P, Danelon D, Bontempo S, Mombro M, Cardaropoli S, Todros T. Fetal cerebral ventriculomegaly: Outcome in 176 cases. *Ultrasound Obstet Gynecol*. 2005;25(4):372-7.
4. Glenn OA, Barkovich AJ. Magnetic resonance imaging of the fetal brain and

- spine: an increasingly important tool in prenatal diagnosis, part 1. AJNR Am J Neuroradiol. 2006;27(8):1604-11.
5. Garcia R, Lederman H, Brandao J. Sonographic evaluation of cerebral ventricular system in healthy, full infants aged 1-6 months. Radiol Brass. 2011; 44(6):1413-1420.
 6. Beryl R, Thomas D, Bryann B, Deborah L. What does MRI add to the parental sonographic diagnosis of ventriculomegaly. Journals of Ultrasound in Medicine. 2007; 26(11):1513-1522.
 7. Cochran DD, Myles ST, Nimrod C, Still DK, Sugaman RG, Wittmann BK. Intrauterine hydrocephalus and ventriculomegaly: Associated anomalies and fetal outcome. Cor.J.Neurol Sci. 1985;12:51-59.
 8. Almond B, Ronini G, Rawven A, Ofer Fainarg, Yaron Z. Fetal lateral ventricular width: what is its limit? Journal of Ultrasound in Medicine. 2003;(1):39-43.
 9. Pilu G, Perolo A, Falco P, Visentin A, Gabrielli S, Bovicelli L. Ultrasound of the central nervous system. Curr Opin Obstet Gynecol. 2000;12:93-103.
 10. Farrell TA, Hertzberg BS, Kliewer MA, Harris L, Paine SS. Lateral ventricles: Reassessment of normal values for atrial diameter at US. Radiology. 1994;193:409-411.
 11. Patel MD, Filly AL, Hersh DR, Goldstein RB. Isolated mild fetal cerebral ventriculomegaly: Clinical Course and Outcome. Radiology. 1995;192:759-764.
 12. Candoza J, Golstein D, Filly RH. Accession of fetal ventriculomegaly with a single measurement: The width of the lateral ventricular diameter. Department of Radiology, University of California School of Medicine. 2008;169(3):711.
 13. McIennan A, Pincham V, Peters H. Reassessment of lateral cerebral ventricle measurement and ventriculomegaly. Asum Ultrasound Bull. 2006;9:17-20.
 14. Keith Vantaltren, Michael Bethume, Frank Circio, Paul Lombardo, Michal E, Schneider Kolsky. Routine sonographic measurement of the near-field lateral ventricle during second-trimester morphology scans. 2013;9:1587-1592.
 15. Wax JR, Bookman L, Cartin A, Pinette MG, Blackstone J. Mild fetal cerebral ventriculomegaly: Diagnosis, clinical associations and outcomes, Obstet Gynecol Surv. 2013;407-414.
 16. Pretorius DH, Drose JA, Manco-Johnson ML. Fetal lateral ventricular ratio determination during the second trimester. J Ultrasound Med. 1986;5:121-124.
 17. Hilpert PL, Hall BE, Kurts AB. The atria of the fetal ventricles: A sonographic study of normal atrial size and choroid plexus volume. AJR Am J Roentgenol. 1995; 164:731-734.
 18. Siedler DE, Filly RA. Relative growth of higher fetal brain structures. J Ultrasound Med. 1987;5:73-576.
 19. Parilla B, Budness L, Dinsmor M, Curran L. In utero progression of mild fetal ventriculomegaly. International journal of mild fetal ventriculomegaly. International Journal of Gynecology Obsteric. 2006;93: 106-109.

© 2019 Udoh et al.; This is an Open Access article distributed under the terms of the Creative Commons Attribution License (<http://creativecommons.org/licenses/by/4.0>), which permits unrestricted use, distribution, and reproduction in any medium, provided the original work is properly cited.

Peer-review history:
The peer review history for this paper can be accessed here:
<http://www.sdiarticle3.com/review-history/34770>