

## **Histological Effect of Different Inhalants on the Heart and Lungs of Wistar Rats**

**U. S. Aguwa<sup>1\*</sup>, B. N. Obinwa<sup>1</sup> and C. E. Eze<sup>1</sup>**

<sup>1</sup>*Anatomy Department, Nnamdi Azikiwe University, Nnewi Campus, Nigeria.*

### **Authors' contributions**

*This work was carried out in collaboration among all authors. Author USA designed the study, wrote the protocol, wrote the first draft of the manuscript and managed the analyses of the study. Authors BNO and CEE managed the literature search and performed the statistical analysis. All authors read and approved the final manuscript.*

### **Article Information**

#### Editor(s):

(1) Dr. Christopher Edet Ekpenyong, University of Uyo, Nigeria.

#### Reviewers:

(1) Neide Martins, State University of Western Paraná, Brazil.

(2) Vânia Thais Silva Gomes, University of Gurupi, Brazil.

Complete Peer review History: <http://www.sdiarticle4.com/review-history/62918>

**Original Research Article**

**Received 10 September 2020**

**Accepted 17 November 2020**

**Published 09 December 2020**

### **ABSTRACT**

Most inhalation methods of animal sacrifice target the respiratory and circulatory systems. Chances are that chemical inhalation methods of animal euthanasia for studies involving the heart and lungs may interfere with the outcome of the research. This study was done to evaluate the effect of the inhalation of chloroform, diethyl ether and formalin as methods of animal sacrifice on the cytoarchitecture of the heart and lungs of Wistar rats. Twenty adult male rats were divided into 4 groups of 5 rats each and acclimatized for 2 weeks. After acclimatization, the rats were sacrificed by cervical dislocation (control), chloroform inhalation, diethyl ether inhalation and formalin inhalation for groups A, B, C and D respectively. The heart and lungs were removed from the rats and fixed in 10% formal saline for histological studies using the haematoxylin and eosin method. Results show that none of the chemical agents inhaled had adverse effects on the histology of the hearts of the rats. On the contrary, the chemicals inhaled showed adverse effects on the histology of the lungs, ranging from tissue and cellular necrosis, inflammation and cytoarchitectural distortion of lung tissues. We can therefore conclude that inhalation methods of sacrifice are not ideal when researching on the lungs but on the heart they can be used based on the findings of this research.

*Keywords: Heart; lungs; method of sacrifice; chloroform; diethyl ether; formalin; cervical dislocation.*

\*Corresponding author: E-mail: [usaguwa@gmail.com](mailto:usaguwa@gmail.com);

## 1. INTRODUCTION

Every step in animal research is critical in determining the final outcome of a research. Starting from animal handling to the dosage and route of administration (where it applies), to the method of animal sacrifice, tissue harvesting and the handling and processing of harvested tissues, all are essential in determining the smooth ending of the research process [1,2,3].

Animal sacrifice amongst others is one of the most critical of the highlighted methods. The organs of experimental animals respond to toxic agents in minutes after exposure [4,5]. The period of sacrifice therefore is sufficient to induce toxicity on the target organs. This effect is capable of falsifying the real outcome of a research. There are reports showing that inhalation methods of sacrifice such as used in this research have shown adverse effects on the brain [6], liver and kidney [7] of Wistar rats. Other reports suggest that the use of CO<sub>2</sub> or argon for rat sacrifice caused increased heart rate and blood pressure [8]. Although CO<sub>2</sub> and argon both lead to death by hypoxia, CO<sub>2</sub> directly depresses the central nervous system, causing cardiac suppression and loss of consciousness. Argon gas in contrast is an inert gas and results in death when O<sub>2</sub> is displaced. Reports have shown that argon gas, when used at concentrations sufficient for euthanasia, led to behaviours including rearing, gasping, and seizure-like activity [8]. These behavioural responses suggest that rats experience distress prior to loss of consciousness during euthanasia with argon. This is similar to the report of Aguwa et al. [6] when rats were euthanized with diethyl ether. Reports suggest that argon at a concentration sufficient to cause death is stressful to rats as a sole euthanasia agent [9]. There is hardly any physiological change without a corresponding anatomical and cytological interference whether positive or negative [10]. It is therefore expedient to study the histological effect of these methods on the heart and lungs of Wistar rats. Most researches in the basic medical sciences review the histological of the target organ. Making histological inferences from error in animal sacrifice can lead to false positive results which may amount to scientific deception. Hence, in this research, without prior exposure of the rats to any agent, we sought to evaluate the impact of these common methods of rat euthanasia to the heart and lungs of Wistar rats.

Researches on the heart and lungs have become very crucial in the light of current global trends. In

recent years, the world has been faced with severe respiratory system-targeted diseases, ranging from severe acute respiratory syndrome (SARS), bird flu, Ebola virus, Nipah virus, influenza A, acute lower respiratory infections, tuberculosis [11] and the most recent covid-19. All of these diseases have symptoms that lead to respiratory distress and most deaths due to these diseases are associated with respiratory failure. The target of natural and artificial disease causing agents on the lungs and respiratory system have made research in this area of utmost important [12]. Cardiovascular diseases (CVDs) on the other hand are among the most frequent causes of mortality globally. An estimated 17.5 million people died from CVDs in 2012, representing 31% of all global deaths, an increase from 30% in 2008 [13]. There is a paucity of data on the inhalational effects of formalin, diethyl ether and chloroform on the heart and lungs of Wistar rats. This study was undertaken to bridge that knowledge gap.

## 2. MATERIALS AND METHODS

Twenty adult male Wistar rats weighing between 150 to 180g were used for this study. The rats were housed in well ventilated standard wooden cages. They were fed pelletized rat feed produced by Pfizer. Animals were separated into 4 groups of five (5) rats each based on closeness to weight. The rats were acclimatized for 2 weeks under standard conditions for handling research animals. Research was approved by the research ethics sub-committee (Anatomy Department) of the Faculty of Basic Medical Sciences, Nnamdi Azikiwe University, Nnewi campus. Post-acclimatization, rats were subjected to their corresponding chemicals for inhalation, sedation and sacrifice as follows: Group A (control) were not exposed to any inhalable chemical agent but were sacrificed by cervical dislocation, Group B rats were exposed to chloroform, Group C rats were exposed to diethyl ether and Group D rats were exposed to formalin. All chemicals used were manufactured by SIGMA-ADRIK, INC., P.O. Box 14508, St. Louis, MO 63178, USA and bought from local accredited chemical dealers.

Rats in groups B, C and D were introduced to a desiccator containing their corresponding chemical. Prior to exposure, the chemical was soaked in cotton wool and placed in the desiccator for 5minutes to ensure circulation. The time taken for the rats to pass out was recorded using a stop watch. Maximum time allowed was

30 minutes, after which any unsedated rat was sacrificed by cervical dislocation. Afterwards the heart and lungs of the rats were excised and fixed in 10% formal saline for histological studies.

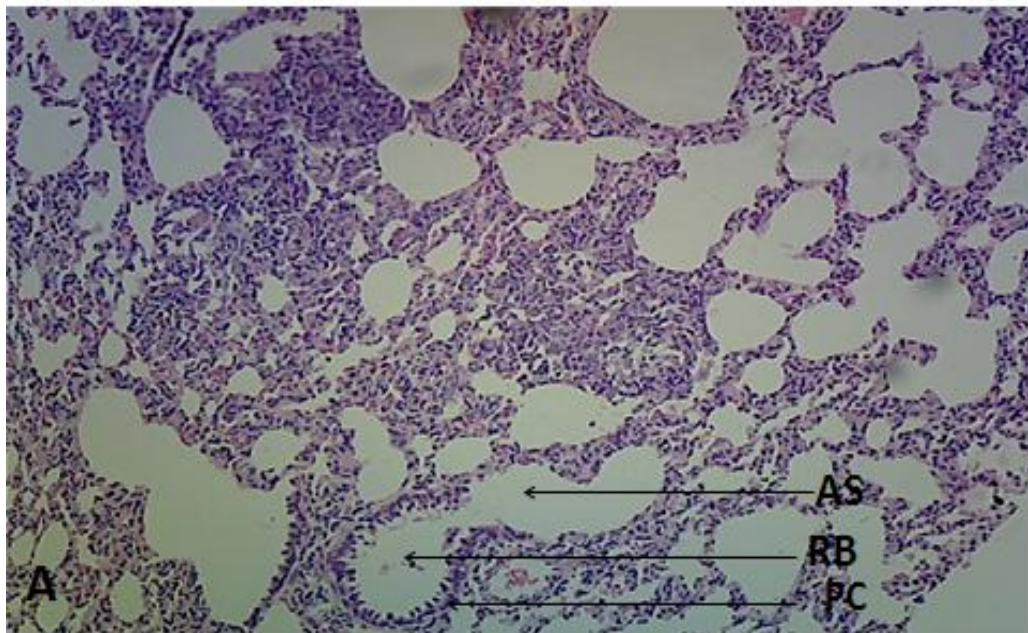
## 2.1 Histopathological Studies

After 48 hours of fixation, tissues were processed using the H&E procedure according to the method of Drury and Wallington [13]. Tissues were placed in ascending grades of alcohol (70%, 80%, 90%) for one hour each and in absolute (100%) twice, one hour each time. Tissues were then transferred to two changes of xylene for one hour each. Tissues were embedded in four changes of molten paraffin wax at constant temperatures of 36-60°C in an oven of paraffin bath for one hour each. Metal blocks were taken and filed with paraffin wax and tissues were placed in it immediately with forceps face. When the paraffin cools, the solid paraffin is formed ready for sectioning. Thin sections were cut at 5µm using a rotary microtome after excess paraffin wax was trimmed off. The sliced tissue ribbons were spread on water in the water bath maintained at 50-55°C and picked up with a pre-labeled glass slide already made sticky using egg albumin. Water was drained off and the slide is put in an incubator so that the section is completely fixed on the slide and becomes dry. Haematoxylin and eosin staining was done

according to the procedure described by Drury and Wallington [13]. Sections were dewaxed in two changes of xylene lasting for two minutes each, rehydrated in descending grades of alcohol, 100%, 95%, 90%, 70%, 50% ethanol for two minutes in each grade and rinsed in distilled water. Sections were then stained in haematoxylin for ten to fifteen minutes and washed in running tap water for 2-3 minutes and examined microscopically to confirm sufficient degree of staining. Tissue was differentiated in 1% HCL acid for a few seconds to remove excess stain. Sections were then washed in running tap water for 15 minutes to regain the blue colour and then stained in 1% aqueous eosin for about 5 minutes. Surplus stain was washed off in running tap water and mounted in distrene plasticizer xylene (DPX) using clean glass cover slide. Tissues were then focused under Leica research light microscope and photomicrographs taken from each group and labeled using Microsoft power point.

## 3. RESULTS

The results below are representative photomicrographs of rat heart and lungs from groups A-D. The heart tissues appear normal in all exposed groups compared to the control. The lungs tissues however had varying degrees of cytoarchitectural distortions.



**Plate 1. Representative photomicrograph of rat lungs from the control group A showing normal lung tissue with prominent respiratory bronchiole (RB) surrounded by pneumocytes (PC). Also present are alveolar sacs (AS). X400**

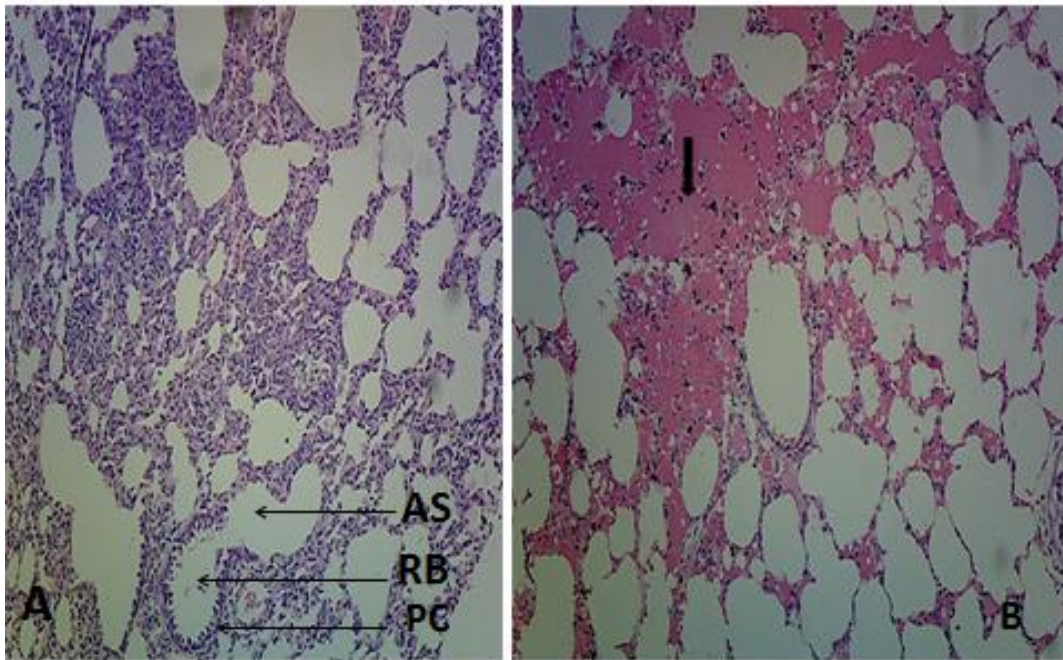


Plate 2. Representative photomicrograph of rat lungs comparing group B rats to the Control group A. The group A lungs appears normal. However, the group B lung micrograph shows regions of tissue damage (arrow). X400

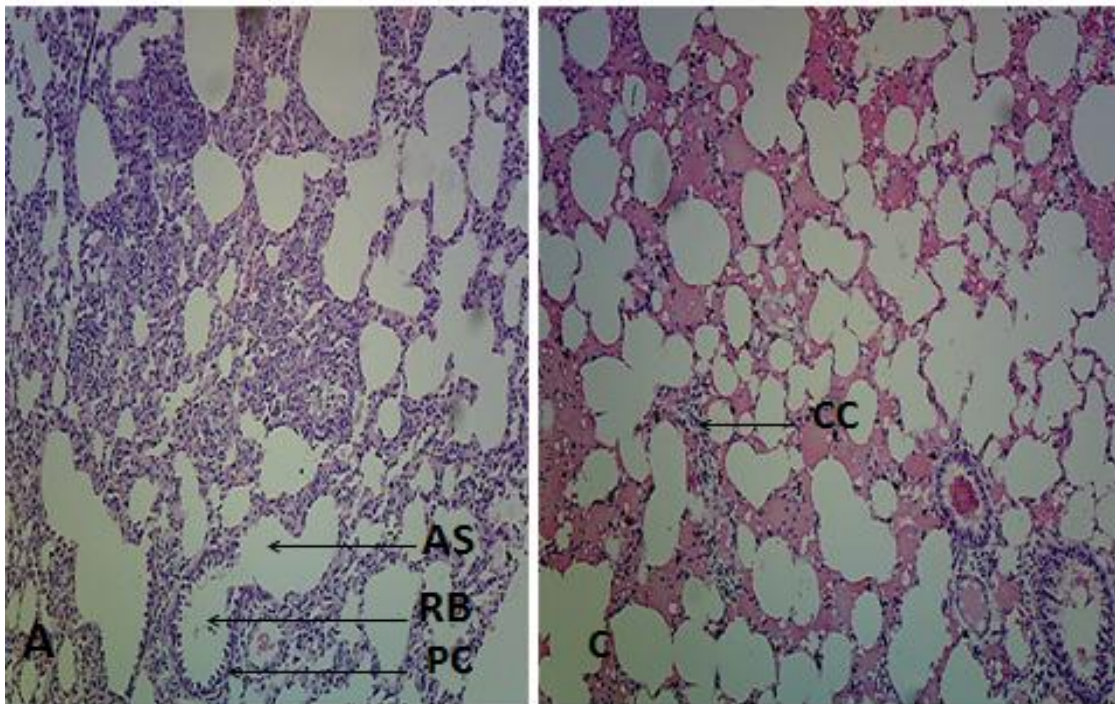
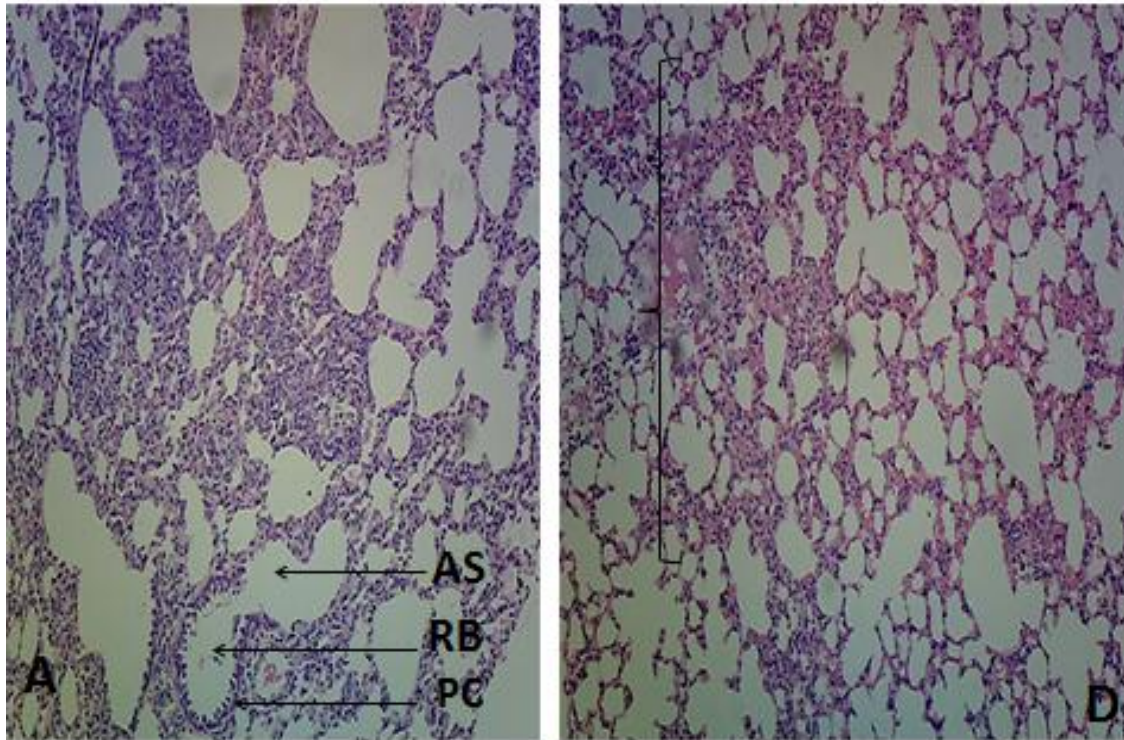
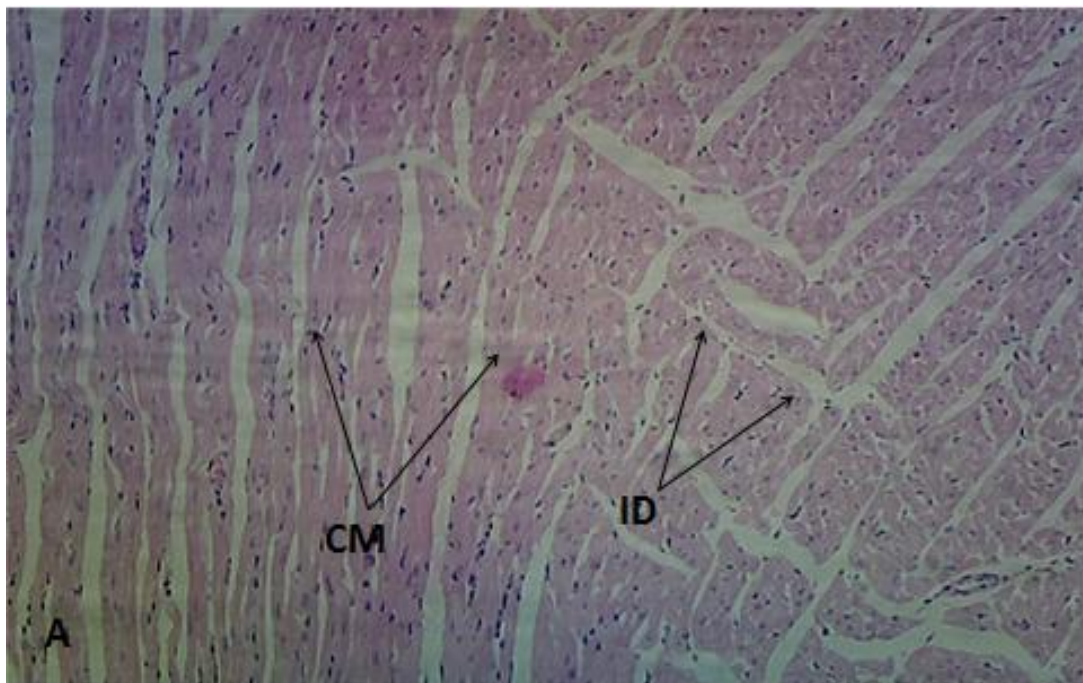


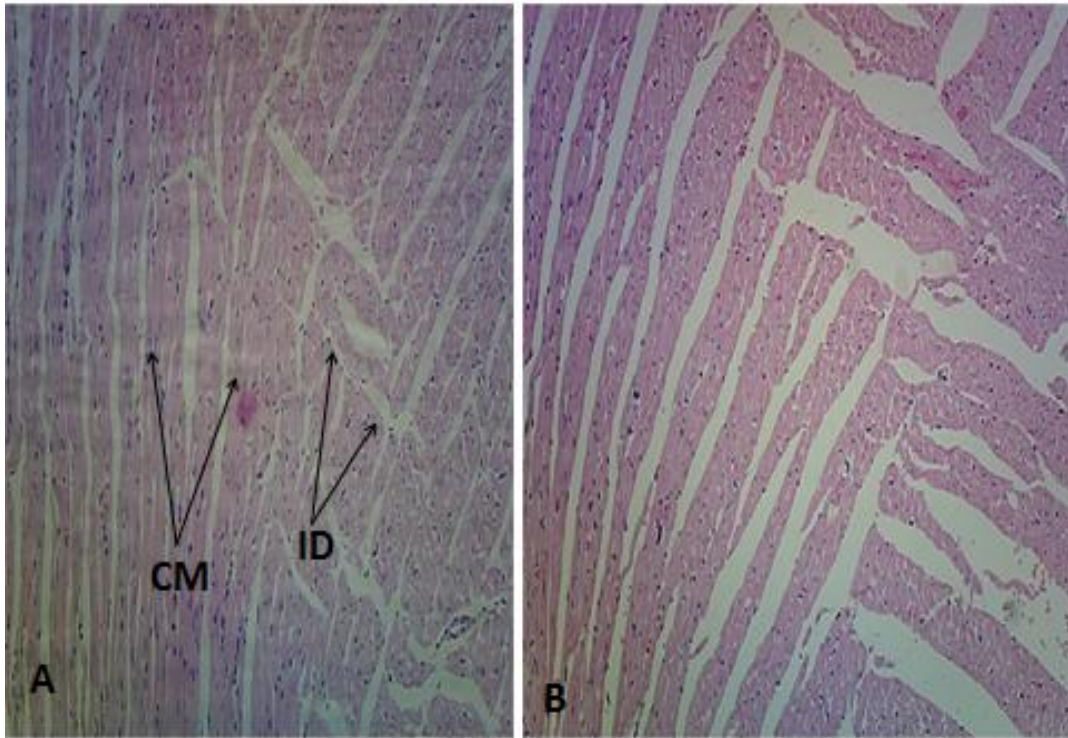
Plate 3. Comparing the micrograph of rat lungs in group C with the control group A. Group C lungs show sparse cellular distribution and cellular congestion in different regions (arrow). X400



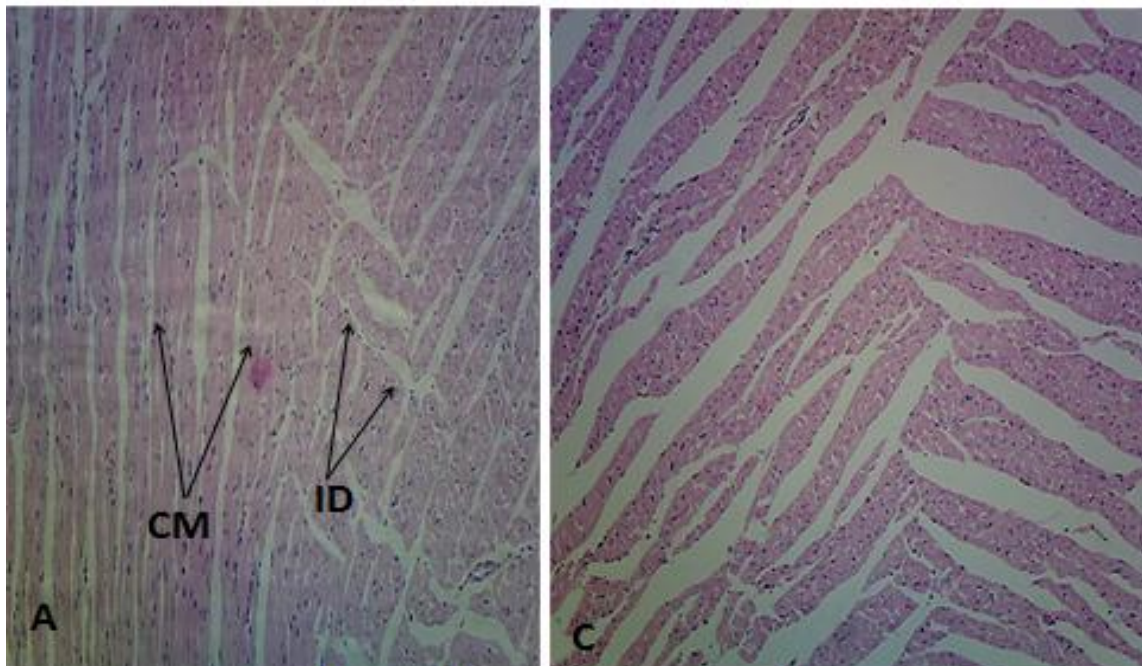
**Plate 4. Representative photomicrograph of rat lungs comparing group D with the control group. Group D lungs show areas of necrosis. X400**



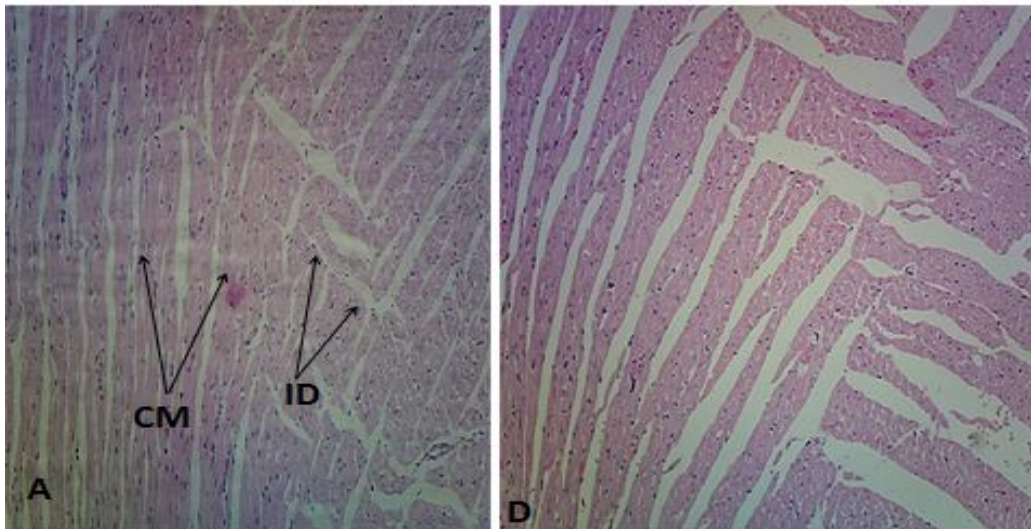
**Plate 5. Representative photomicrograph of rat heart in group A (control) showing normal cardiac muscles (CM) and intercalated discs (ID).H&E X100**



**Plate 6. Representative photomicrograph of rat heart comparing Group A (control) with group B. Group A shows normal cardiac muscles (CM) and intercalated discs (ID). Group B shows normal heart tissue comparable to that in the control group A. H&E X100**



**Plate 7. Representative photomicrograph of rat heart comparing group C to Group A. the heart tissue of rats in group C show normal architecture**



**Plate 8. Representative photomicrograph of rat heart comparing group D with the control group A. Group D rats show normal heart tissue comparable to A.s**

#### 4. DISCUSSION

The haematoxylin and eosin (H&E) analysis of the lungs and heart tissue reveal that only cervical dislocation was safe for the lungs. The rest of the methods showed several degrees of tissue damage. Chloroform inhalation (plate 2) resulted in tissue death as seen on the micrograph with an area of tissue inflammation. This is in line with the report of Aguwa et al., [6] which suggest that chloroform inhalation adversely affected the cytoarchitecture of the cerebellum [6] of Wistar rats. Inhalation of chloroform at concentrations in the range of 10 – 100 gm-3 for few minutes was reported to induce anaesthesia in mice, rabbits, guinea pigs and cats with resulting cardiac effects including decreased diastolic pressure, reduction of stroke volume and decreased cardiac output. Hoyle and Svendsen [14] reported that chlorine inhalation damages the respiratory tract, including the airways and distal lung, and can result in acute lung injury. Acute exposures can result in symptoms of acute airway obstruction including wheezing, cough, chest tightness, and/or dyspnea [15].

Diethyl ether and formalin inhalation also showed tissue inflammation, sparse cellular distribution, cellular congestion and tissue necrosis. It was reported that diethyl ether as well as formalin inhalation adversely affected the histology of the cerebellum, hippocampus, liver and kidney of Wistar rats sacrificed by these methods [6,7]. In other reports, ether anaesthesia resulted in

increased cardiac output in dogs [16,17]. Formalin, a commercial preparation of formaldehyde, has been used for animal sedation in researches [18]. Although classified by the IARC as "carcinogenic in humans" (class 1) [19], it is still widely used in anatomy and pathology departments for the fixing and preservation of biological tissues. According to Gulec et al. [20], formalin inhalation stimulates oxidative stress and some secondary toxic effects in cardiac cells and tissue.

Similarly, reports suggest that the use of CO<sub>2</sub> or argon for rat sacrifice caused increased heart rate and blood pressure [8]. Although CO<sub>2</sub> and argon both lead to death by hypoxia, CO<sub>2</sub> directly depresses the central nervous system, causing cardiac suppression and loss of consciousness. Argon gas in contrast is an inert gas and results in death when O<sub>2</sub> is displaced. Reports have shown that argon gas, when used at concentrations sufficient for euthanasia, led to behaviors including rearing, gasping, and seizure-like activity [8]. These behavioral responses suggest that rats experience distress prior to loss of consciousness during euthanasia with argon. Reports suggest that argon at a concentration sufficient to cause death is stressful to rats as a sole euthanasia agent [9]. This is similar to our observation when rats were euthanized with diethyl ether.

Because of the confounding variables affecting heart rate during euthanasia, we think behavioral observations provide a more sensitive measure

of the experience of rats during this procedure. All rats euthanized with argon demonstrated convulsive muscles spasms, and 3 of 7 arched their backs and exhibited open-mouth breathing while still appearing conscious. These behaviors suggest that rats euthanized with argon were experiencing stress before losing consciousness [21]. In contrast, rats exposed to CO<sub>2</sub> did not exhibit any overt examples of distress such as gasping or seizures. These findings are in contrast to studies that have described altered respiration in rats during CO<sub>2</sub> exposure such as "gasping and asphyxia" and "gasping or labored breathing." [22]. The current study is the first to demonstrate that rats euthanized with argon gas have pulmonary lesions, specifically hemorrhage into the alveoli, consistent with terminal asphyxiation.

The heart of rats in all groups appeared normal, method of sacrifice notwithstanding.

Aguwa et al. [6] reported that different chemical agents commonly used as sedatives for rat euthanasia in Nigeria showed adverse effects on the cerebellum and hippocampus in Wistar rats [6]. In another report, the same author also reported different degree of adverse effects of chloroform, diethyl ether and formalin on the liver and kidneys of Wistar rats [7]. It therefore became expedient to go further to investigate the effects of the same set of chemical agents on the heart and lungs. The present result is in conformity with these previous reports as our result showed adverse effects in rat lungs in groups B, C and D exposed to chloroform, diethyl ether and formalin respectively. The present result is however different for the heart tissue. The heart tissue of the rats in all groups appeared normal compared to the control group. This means that contrary to previous reports and the present report on the lungs, it may not be wrong to use any of the methods of sacrifice used in this study when studying the heart. Different researches abound to prove that the chemicals used as sedatives in animal sacrifice are not entirely safe [6,7]. Although they achieve humaneness to a great degree, there are reports that they may interfere with the outcome of the research. There is no clear standard as to which method of sacrifice to employ under a particular research protocol.

## 5. CONCLUSION

It can be concluded from this research that the inhalation methods of rat euthanasia used in this research posed no threat to the histology of the

heart tissue. The same cannot be said of the lung tissue as several cytoarchitectural distortions were observed in all the inhalation methods.

## 6. RECOMMENDATION

It is therefore our recommendation that cervical dislocation is the best method out of the four common methods of sacrifice used by Nigerian researchers for serum chemistry as well as histology and histopathological studies of liver and kidney tissues.

## CONSENT AND ETHICAL APPROVAL

As per international standard or university standard guideline participant consent and ethical approval has been collected and preserved by the authors.

Animal Ethic committee approval has been taken to carry out this study.

## COMPETING INTERESTS

Authors have declared that no competing interests exist.

## REFERENCES

1. Antonini A, Fagiolini M, Stryker MP. Anatomical correlates of functional plasticity in mouse visual cortex. *Journal of Neuroscience*. 1999;19(11):4388-4406.
2. Cooke RF, Bohnert DW, Cappelozza BI, Mueller CJ, Delcurto T. Effects of temperament and acclimation to handling on reproductive performance of *Bos taurus* beef females. *Journal of Animal Science*. 2012;90(10):3547-3555.
3. Stutler SA, Johnson EW, Still KR, Schaeffer DJ, Hess RA, Arfsten DP. Effect of method of euthanasia on sperm motility of mature Sprague-Dawley rats. *Journal of the American Association for Laboratory Animal Science*. 2007;46(2):13-20.
4. Brooks SP, Lampi BJ, Bihun CG. The influence of euthanasia methods on rat liver metabolism. *Journal of the American Association for Laboratory Animal Science*. 1999;38(6):19-24.
5. Blackshaw JK, Fenwick DC, Beattie AW, Allan DJ. The behaviour of chickens, mice and rats during euthanasia with chloroform, carbon dioxide and ether. *Laboratory Animals*. 1988;22(1):67-75.



6. Aguwa et al., Evaluating Methods of Rat Euthanasia on the Liver and Kidney of Wistar Rats: Cervical Dislocation, Chloroform Inhalation, Diethyl Ether Inhalation and Formalin Inhalation Let Health BiolSci. 2020;5(1):8-13.
7. Aguwa US, Okeke SN, Ezejindu DN, Eze CE, Azurunwa O, Obinwa BN, Ovie FO et al. Evaluating the Effect of Chloroform Inhalation as a Method of Euthanasia on the Cerebellum and Hippocampus of Adult Wistar Rats. Journal of Advances in Medical and Pharmaceutical Sciences. 2020;14-25.  
Available:<https://doi.org/10.9734/jamps/2020/v22i630176>.
8. Sharp J, Azar T, Lawson D. Comparison of carbon dioxide, argon, and nitrogen for inducing unconsciousness or euthanasia of rats. J Am Assoc Lab Anim Sci. 2006; 45:21–25.
9. Tanya H Burkholder,1,\* Lee Niel,2 James L Weed,1 Lauren R Brinster,1 John D Bacher,1 and Charmaine J Foltz1. Comparison of Carbon Dioxide and Argon Euthanasia: Effects on Behavior, Heart Rate, and Respiratory Lesions in Rats. Journal of the American Association for Laboratory Animal Science Copyright 2010 by the American Association for Laboratory Animal Science. 2010;49(4): 448–453.
10. World Health Organization. The world health report: 1999: making a difference. World Health Organization; 1999.
11. Anthony Fauci 2001- Infectious Diseases: considerations for the 21<sup>st</sup> century. Clinical infectious Diseases. 2001;32(5):675-685.  
Available:<https://doi.org/10.1086/319235>
12. Anthony Fauci 2001- Infectious Diseases: considerations for the 21<sup>st</sup> century. Clinical infectious Diseases. 2001;32(5) i.: 675-685.  
Available:<https://doi.org/10.1086/319235>).
13. Collins DR, Tompson AC, Onakpoya IJ, Roberts N, Ward AM, Heneghan CJ. Global cardiovascular risk assessment in the primary prevention of cardiovascular disease in adults: systematic review of systematic reviews. BMJ Open. 2017;7: e013650.
14. Hoyle GW, Svendsen ER. Persistent effects of chlorine inhalation on respiratory health. Annals of the New York Academy of Sciences. 2016;1378(1).
15. White CW, Martin JG. Chlorine Gas Inhalation: Human Clinical Evidence of Toxicity and Experience in Animal Models. Proceedings of the American Thoracic Society. 2010;7(4):257-263.
16. Collins DR, Tompson AC, Onakpoya IJ, Roberts N, Ward AM, Heneghan CJ. Global cardiovascular risk assessment in the primary prevention of cardiovascular disease in adults: systematic review of systematic reviews. BMJ Open. 2017;7: e013650.
17. Gersh BJ, Sliwa K, Mayosi BM, Yusuf S. Novel therapeutic concepts: the epidemic of cardiovascular disease in the developing world: Global implications. Eur Heart J. 2010;31:642-648.
18. Niel L, Weary DM. Behavioural responses of rats to gradual fill carbon dioxide euthanasia and reduced oxygen concentrations. Appl Anim Behav Sci. 2006;100:295–308.
19. Niel L, Weary DM. Rats avoid exposure to carbon dioxide and argon. Appl Anim Behav Sci. 2007;107:100–109.
20. Gulec M, Songurb A, Sahinc S, Ozenb AO, Sarsilmazd M, Omer Akyole O. Antioxidant enzyme activities and lipid peroxidation products in heart tissue of subacute and subchronic formaldehyde-exposed rats: A preliminary study. Toxicology and Industrial Health. 2006;22: 117-124.
21. Makowska IJ, Niel L, Kirkden RD, Weary DM. Rats show aversion to argon-induced hypoxia. Appl Anim Behav Sci. 2008; 114:572–581.
22. Leach MC, Bowell VA, Allan TF, Morton DB. Aversion to gaseous euthanasia agents in rats and mice. Comp Med. 2002;52:249–257.

© 2020 Aguwa et al.; This is an Open Access article distributed under the terms of the Creative Commons Attribution License (<http://creativecommons.org/licenses/by/4.0>), which permits unrestricted use, distribution, and reproduction in any medium, provided the original work is properly cited.

*Peer-review history:*  
*The peer review history for this paper can be accessed here:*  
<http://www.sdiarticle4.com/review-history/62918>