



## The Ileosigmoid Knot as a Rare Cause of Intestinal Occlusion: Report of Two Cases

Fatimazahra Bensardi<sup>1</sup>, Bassam Daif<sup>1\*</sup>, Ahmed Ballati<sup>1</sup>, Mohamed Ouchane<sup>1</sup>, Othmane Elyamine<sup>1</sup>, Mounir Bouali<sup>1</sup>, Abdelilah Elbakouri<sup>1</sup>, Khalid Elhattabi<sup>1</sup> and Abdelaziz Fadil<sup>1</sup>

<sup>1</sup>Visceral Surgical Emergency Department, Ibn Rochd University Hospital, Casablanca, Morocco.

### Authors' contributions

This work was carried out in collaboration among all the authors. Author FB is the operating surgeon. Author FB wrote the protocol and wrote the first draft of the manuscript. Authors BD and AB managed the documentary research, wrote the manuscript and proposed the work for publication. Authors worked on the documentary searches. All authors read and approved the final manuscript.

### Article Information

#### Editor(s):

(1) Dr. Luis Ricardo Martinhao Souto, Universidade de Marília (UNIMAR), Brazil.

#### Reviewers:

(1) Shigeki Matsubara, Jichi Medical University, Japan.

(2) Takayuki Shimizu, Dokkyo Medical University, Japan.

(3) Tolga Dinc, Ankara city hospital, Turkey.

Complete Peer review History: <http://www.sdiarticle4.com/review-history/56174>

Case Study

Received 07 February 2020

Accepted 12 April 2020

Published 15 April 2020

### ABSTRACT

The ileo-sigmoid knot is a rare cause of intestinal obstruction, which usually requires emergency life-saving surgery. In this condition the ileum and sigmoid colon are twisted around each other in a knot, causing strangulation. We here report 2 cases with ileo-sigmoid knot. In both cases, the diagnosis was only made intraoperatively. Resection and colostomy were made, with the latter closed later. Both showed good prognoses. Physicians should be aware that ileo-sigmoid knot may be hidden behind intestinal obstruction.

*Keywords:* ileo-sigmoid node; intestinal occlusion; necrosis.

### 1. INTRODUCTION

The ileosigmoid node or double ileosigmoid volvulus is a rare cause of acute intestinal

obstruction by strangulation, which is defined by the coiling of the small intestine at the base of the sigmoid colon and forms a knot causing strangulation that rapidly progresses to necrosis.

\*Corresponding author: E-mail: [dr.daif.bassam@gmail.com](mailto:dr.daif.bassam@gmail.com);

This clinical entity is exceptional in Western countries, but is common in some African and Middle East Asian nations [1]. Knowledge of the mechanism of this pathology is essential for early diagnosis and rapid and appropriate surgical management.

## 2. PATIENTS AND OBSERVATIONS

### 2.1 Case 1

A 55 year old man, with no previous medical history, admitted to the emergency room for an occlusive syndrome, which has been evolving for 4 days. On admission, patient in a state of hemodynamic shock, hypothermic at 35.7°C, BP=8/5 mmHg, abdomen sensitive to palpation, free hernial orifices, rectal exam with empty ampullae. At the abdominal CT scan: distension of the colon and some part of the small intestine upstream of a transitional level made of a turn of the sigmoid colon and its meso realizing

mechanical colonic occlusion on sigmoid volvulus with sign of digestive distress.

Direct referral to the operating theatre after conditioning, and under antibiotic coverage, surgical exploration had found a small intestine volvulus around the sigmoid base in the form of a node, with necrosis of the right colon, of the graft over 2 m at 20 cm from the ileocecal junction and necrosis of the sigmoid loop (Figs. 1,2,3). The patient underwent right hemicolectomy with 2.20 m of the small intestine and sigmoid colon, with terminal ileocolic anastomosis and Hartmann-type left iliac colostomy. The patient stayed in intensive care postoperatively for 3 days, with transfusion of 3 red blood cells and 7 fresh frozen plasma. The postoperative follow-up was simple, and the patient was discharged postoperatively on day 5. Five weeks later the patient was operated on to re-establish colonic continuity.

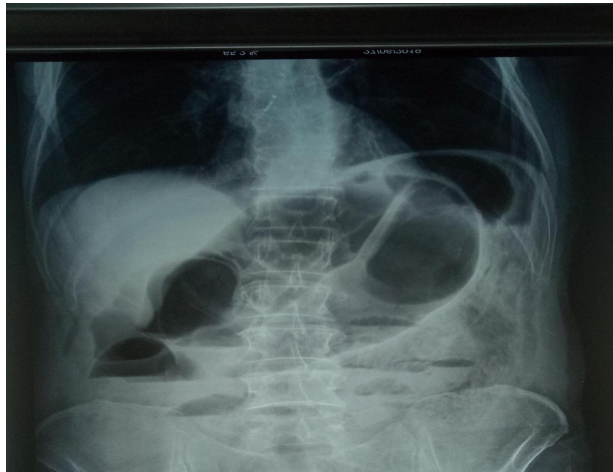

Fig. 1. Abdomen without preparation standing up

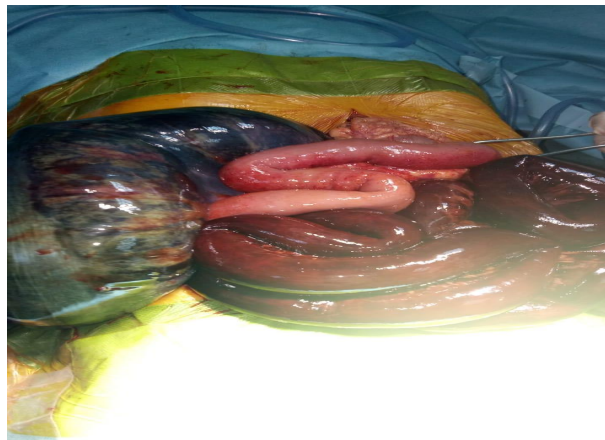
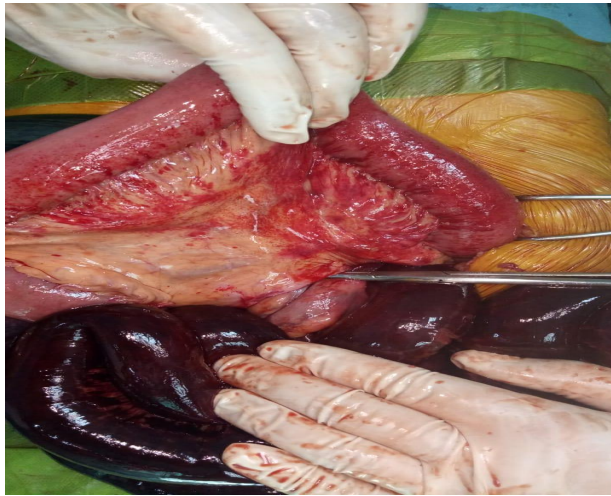
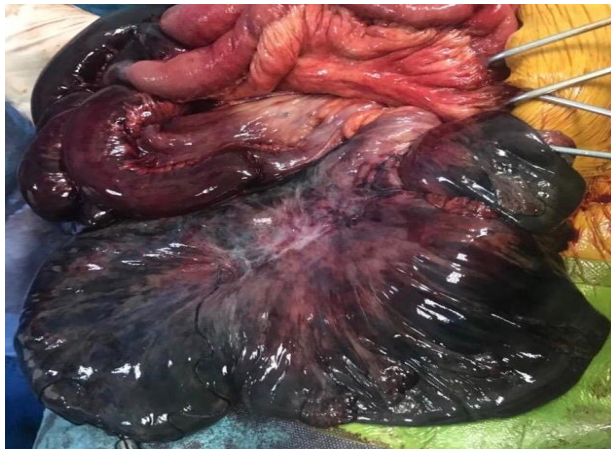

Fig. 2. Intraoperative view of the ileal node around the base of the sigmoid



**Fig. 3. Intraoperative view of the ileal node around the base of the sigmoid**



**Fig. 4. Intra-operative view after node release**

## **2.2 Case 2**

A 30-year-old woman, admitted at postpartum day 4 for an occlusive syndrome. On clinical examination the patient was polypneic and tachycardic, temperature 37°C, BP= 10/6 mmHg. The abdomen was sensitive. Pelvic touch without particularity. Abdominal radiography showed pneumoperitoneum. The patient was operated, and exploration revealed a very advanced stercoral peritonitis following a perforation and small intestine necrosis extending over 60 cm, 30 cm from the ileo-caecal junction, secondary to an ileo-sigmoid node, the sigmoid colon was also necrotic. Surgical intervention consisted of abundant peritoneal lavage, resection of the necrotic digestive segments, with right ileostomy, and a Hartmann-type left colostomy because the necrosis of the sigmoid colon extended to the

rectosigmoid hinge. The patient spent 2 days in intensive care without incident. The patient was discharged on day 7 postoperatively, then readmitted six weeks later for recovery of colonic and small intestine continuity.

## **3. DISCUSSION**

The ileo-sigmoid node is a rare visceral emergency, affecting mostly males [2,3]. It occurs in the majority of cases when a loop of small intestine descends into the left paracolic gutter ties the base of the sigmoid colon and forms a knot. The ileo-sigmoid node is a rare entity, representing 7.6% of all sigmoid volvulus in France [4], but in a minority of cases the sigmoid may be the active component in the onset of strangulation. Depending on the winding force of the node and the participation of the

**Table 1. Classification of the ileosigmoid node according to Atamanalp (2018) [13]**

Classification		Definition	SurgicalStrategy	Mortality (%)	Morbidity (%)
Group	Sub group				
ISK I	ISK IA	G 0, A 0, ASA I-III	Decompression	1-5	5-15
			or/and mesopexy or sigmoid mesoplasty	1-8	10-20
			or/and resection of sigmoid anastomosis	1-10	15-25
ISK II	ISK IB ISK IIA	G 0, A I or ASA IV-V G I, A 0, ASA I-III, B 0	Decompression	10-30	20-40
			Sigmoid or ileal colonic resection and anastomosis	5-20	10-30
			Ileal or sigmoid colon resection and ostomy	20-50	30-60
ISK III	ISK IIIA ISK IIIB	G II, A 0, ASA I-III, B 0 G II, A I or ASA IV-V or BI	Sigmoid and ileal colonic resection and anastomosis	10-30	20-40
			Ileal and sigmoid resection, an anastomosis and a stoma.	30-60	40-80

*A 0, age < 70; A I, age ≥ 70; ASA; B 0, good condition of ileum; B I, presence of ischemia, edema, perforation, or difference in proximal and distal diameter of ileum; G 0, no necrosis; G I, presence of sigmoid or ileal necrosis; G II, presence of necrosis and sigmoid; ISK, ileosigmoid knotting*

mesentery in the node, this strangulation rapidly causes necrosis of the strangulated digestive segments (74-80%) [1-4]. This necrosis may extend to the terminal ileum and even the cecum or ascending colon.

Atamanalp et al. [5] have suggested anatomical predispositions, a very mobile hail with a very long mesentery and a short root can roll up at the foot of the sigmoid colon. A second factor, which is the rapid replication of the jejunum in patients who eat only one meal a day, would favour its wrapping around the empty ileum, carrying away the sigmoid colon [6,7].

Alver et al. [4] classified the ileo-sigmoid node according to the active digestive segment into 4 types: type I the most frequent occurs when the active segment ileum rotates around the sigmoid; type Ia if the twist is clockwise, type Ib counterclockwise. Type II the sigmoid colon is the active segment and wraps around the ileum. Type III when the ileo-cecum rotates on the base of the sigmoid. And indeterminate when it is difficult to dedifferentiate the active component [4,8] and according to this classification by Alver et al. [4] the first case we reported is classified as Type III with significant involvement of the superior and inferior mesenteric vessels, which justified resection of the right colon and the sigmoid loop.

Preoperative diagnosis is difficult because of its rarity and clinical-radiological atypia [1,9]. The patient usually presents with acute localized abdominal pain, then pain becomes constant and generalized associated with vomiting. In 56% of cases, the patient presents with hypovolemic shock [2,9]. Abdominal examination reveals moderate abdominal distension, with abdominal tenderness or defence on palpation, with intestinal silence when intestinal necrosis has already set in. [9,10]. The abdominal radiography may show disproportionate distension with wide hydroaerous levels in the sigmoid colon occupying the right side of the abdomen, with multiple hydroaerous levels of the small intestine on the left side of the abdomen showing a closed-loop double occlusion.

The abdominal CT scan can assist in the diagnosis by showing the sign of a vortex with a medial deviation of the coecum, the descending colon and the upper and lower mesenteric vessels that will converge to this vortex. Intestinal distension as well as signs of late-stage intestinal ischemia [5,8,10] The retention of material in the

proximal, undistended colon and the radial arrangement of the slender coves guide the diagnosis according to Hashimoto et al. [11]. In view of these radiological data of colon occlusion associated with the clinical triad of hail occlusion, the diagnosis of ileo-sigmoid node is plausible in 71% of cases. It is essential to differentiate it from the volvulus from the sigmoid because endoscopic reduction is contraindicated.

The second case of ileo-sigmoid node that we report occurred postpartum in our patient; to our knowledge few cases have been published in the literature. The peculiarity is that pregnancy makes it difficult to diagnose intestinal obstruction, especially when the parturient is already in labour; this is why the diagnosis is usually made late postpartum, and consequently intestinal necrosis is already present, with significant maternal and fetal mortality [12]. In fact, one should not hesitate to suspect the diagnosis of intestinal obstruction during pregnancy when there are signs of calling. After hemodynamic stabilization, emergency laparotomy is necessary and confirms the diagnosis. The ideal surgical procedure in the case of ileo-sigmoid nodes is a controversial issue. When the bowel is viable, some authors opt for the temptation of simple node removal, others prefer resection of the sigmoid colon to prevent recurrence. In the case of intestinal necrosis, resection of the small intestine, colon and node in one piece is recommended. Hail-gelictermi-terminal or latero-coecal anastomosis is the rule, combined with colocolictermi-terminal anastomosis if local and general conditions allow, otherwise a left iliac colostomy is recommended.

#### 4. CONCLUSION

The ileo-sigmoid node is a very rare entity of acute intestinal occlusion and only an early preoperative diagnosis with a rapid surgical management can improve the prognosis of this pathology, by decreasing the morbi-mortality due to the diagnostic delay. The etiology of this pathology still remains poorly elucidated.

#### CONSENT

As per international standard or university standard, patient's consent has been collected and preserved by the authors.

#### ETHICAL APPROVAL

It is not applicable.

## COMPETING INTERESTS

Authors have declared that no competing interests exist.

## REFERENCES

1. Hirano Y, et al. Ileosigmoid knot: Case report and CT findings, *Abdom. Imaging.* 2005;30(6):674-676, DOI: 10.1007/s00261-005-0315-7
2. Johnson CD. An unusual volvulus--the ileosigmoid knot. *Postgrad. Med. J. Postgrad.* 1986;62(723):47-49. DOI: 10.1136/pgmj.62.723.47
3. Raveenthiran V. The ileosigmoid knot: New observations and changing trends. *Dis. Colon Rectum.* 2001;44(8):1196-1200. DOI:10.1007/bf02234644
4. Alver O, Oren D, Tireli M, Kayabaşı B, Akdemir D. Ileosigmoid knotting in Turkey. Review of 68 cases. *Dis. Colon Rectum.* 1993;36(12):1139-1147 DOI: 10.1007/bf02052263
5. Atamanalp SS, et al. Ileosigmoidal knotting: Outcome in 63 patients. *Dis. colon rectum.* 2004;47(6):906-910. DOI: 10.1007/s10350-004-0528-9
6. Shepherd JJ. Ninety-two cases of ileosigmoid knotting in Uganda. *Br. J. Surg.* 1967;54(6):561-566. DOI: 10.1002/bjs.1800540615
7. Fouquet V, et al. Ileosigmoid knotting in a child. The first case report in a French girl. *Gastroenterol. Clin. Biol.* 2006;30(12):1414-1416. DOI: 10.1016/s0399-8320(06)73574-6
8. Baheti AD, Patel D, Hira P, Babu D. Ileosigmoid knot: A case report. *Indian J. Radiol. Imaging.* 2011;21(2):147. DOI: 10.4103/0971-3026.82301
9. Burrah R, Menon A, Pathan H, Ravikanth R, Kilpadi A. The ileosigmoid knot. *Indian J. Surg. Indian J. Surg.* 2010;72(2):140-142. DOI: 10.1007/s12262-010-0023-6
10. Lee SH, Park YH, Won YS. The ileosigmoid Knot. *Am. J. Roentgenol.* 2000;174(3):685-687. DOI: 10.2214/ajr.174.3.1740685
11. Hashimoto T, Yamaguchi J, Fujioka H, Okada H, Izawa K, Kanematsu T. Two cases of ileosigmoid knot: the youngest reported patient and CT finding. *Hepato-gastroenterology.* 2004;51(57):771-773.
12. Ucar NS, Yuksel BC, Hengirmen S. Did ileal knotting trigger labor or did labor cause ileal knotting? Report of a case. *Surg. Today.* 2009;39(5):440-443. DOI: 10.1007/s00595-008-3850-3.
13. Atamanalp SS. A new classification, treatment algorithm and prognosis-estimating system for ileosigmoid knotting. *Colorectal Dis.* 2018;20(3):252-253. DOI: 10.1111/codi.13987

© 2020 Bensardi et al.; This is an Open Access article distributed under the terms of the Creative Commons Attribution License (<http://creativecommons.org/licenses/by/4.0>), which permits unrestricted use, distribution, and reproduction in any medium, provided the original work is properly cited.

### Peer-review history:

The peer review history for this paper can be accessed here:  
<http://www.sdiarticle4.com/review-history/56174>