

A Case Report on Chronic Myeloid Leukemia

**Iluru Umadevi^{1*}, Bethe Mariamma¹, Peetla Dhanalakshmi¹
and Nayakanti Himabindu¹**

¹*Department of Pharmacy Practice, Santhiram College of Pharmacy, Nandyal-518501, Kurnool District, Andhra Pradesh, India.*

Authors' contributions

This work was carried out in collaboration among all authors. All authors read and approved the final manuscript.

Article Information

Editor(s):

(1) Dr. Kumud Kumar Kafle, Tribhuvan University, Nepal.
(2) Dr. Suprakash Chaudhury, Dr. D. Y. Patil Medical College, Hospital & Research Centre, India.

Reviewers:

(1) Maha Atfy, Hospitals of Zagazig University, Egypt.
(2) Diego da Silva, UniEnsino, Brazil.
(3) Massimo Berger, University of Turin, Italy.

Complete Peer review History: <https://www.sdiarticle4.com/review-history/75732>

Case Report

Received 28 August 2021
Accepted 08 November 2021
Published 12 November 2021

ABSTRACT

Chronic Myelogenous Leukemia, which is also called as Chronic Myeloid Leukemia is a white blood cell cancer. The main characteristic of this form of leukemia is chaotic increase in growth of myeloid cells in bone marrow. These cells get accumulated in blood. Chronic Myeloid Leukemia is a clonal bone marrow stem cell disorder whereupon, proliferation of mature granulocytes (Neutrophils, Eosinophils and Basophils) and their precursors occurs. In this, translocation of chromosome called Philadelphia chromosome is characteristically found associated with myeloproliferative neoplasm. We report a case of 26 years old female patient who is having the clinical presentations of Chronic Myeloid Leukemia. In this case, the patient is having the substantial increase in the white blood cell count and the conditions of Hepatomegaly, Splenomegaly and Grade-I bilateral parenchymal changes. The treatment given to the patient was mainly aimed to control and decrease the white blood cell count.

Keywords: *Chronic myeloid leukemia; Philadelphia chromosome; myeloproliferative neoplasm; Hepatomegaly; Splenomegaly.*

1. INTRODUCTION

Chronic Myeloid Leukemia is certainly a large studied human malignancy. Philadelphia chromosome abnormality which is the principal cause of Chronic Myeloid Leukemia was discovered in 1960-61. This was the first compatible chromosomal abnormality correlated with a distinct type of leukemia. It was a great discovery in cancer biology [1]. Signs and Symptoms include fatigue, weight loss, night sweats, low-grade fever, recurring infections, abdominal fullness, early satiety and lymphadenopathy, Hepatomegaly, Splenomegaly, Sternal tenderness are the physical examination findings [2,3]. In the pathogenesis of Philadelphia(Ph) chromosome positive leukemia, the vital role was known to be played by BCR-ABL chimeric protein especially in Chronic Myeloid Leukemia [4]. Riveting evidence showed that ABL- proto oncogenes was involved on chromosome-9 and previously a gene which is not known on chromosome-22, then termed as BCR for breakpoint cluster region [5]. Rearrangement of BCR-ABL gene produces clonal expansion primarily in CML. Then blockage of apoptosis, genetically programmed autonomous cell death occurs [6]. BCR-ABL gene also induces Anti-apoptotic signals by causing cellular assistance to cytotoxic anti-tumor agents [4]. The diagnostic techniques of Chronic Myeloid Leukemia include Chromosome Banding Analysis, Southern Blot, Fluorescence In-situ Hybridization and Polymerase Chain Reaction. These techniques diagnose the progression and phases of cell cycle at which cancer cells are present [7]. Treatment includes Tyrosine kinase inhibitors

and the surgical procedures like bone marrow transplantation [8]. Imatinib was considered to be the first line agent for treating Chronic Myeloid Leukemia [9,10].

2. CASE REPORT

A female patient of age 25 years was reported to Oncology department with complaints of abdominal discomfort, loss of appetite, early satiety for 3 months. In the Ultrasound scan of whole abdomen, the impression found was Hepatomegaly, Splenomegaly and possible grade-I renal parenchyma changes. In Complete Blood Picture, there was drastic increase in white blood cell count and the value of Total Neutrophils, Eosinophils, Monocytes, Lymphocytes was found to be 0%. In Bone Marrow aspiration test, the myeloid series were severely increased in number with the presence of Basophils shift to left and 7% blasts. Myelocyte peaks were seen. Bone Marrow aspiration test along with Peripheral Smear findings proved that the condition was Chronic Myeloid Leukemia-Chronic Phase. The patient was treated with Imatinib drug which is a Tyrosine Kinase Inhibitor and this prescribed for 18 cycles in which one cycle is up to the time period of 3 months. After first cycle of treatment the immune system of the patient had a great response and the values of differential count became normal within the range. As the count of Total white blood cells reached normal the number of cells destruction decreased thereby curing hepatomegaly and Splenomegaly. The patient was alive and is continuing the treatment of Imatinib.

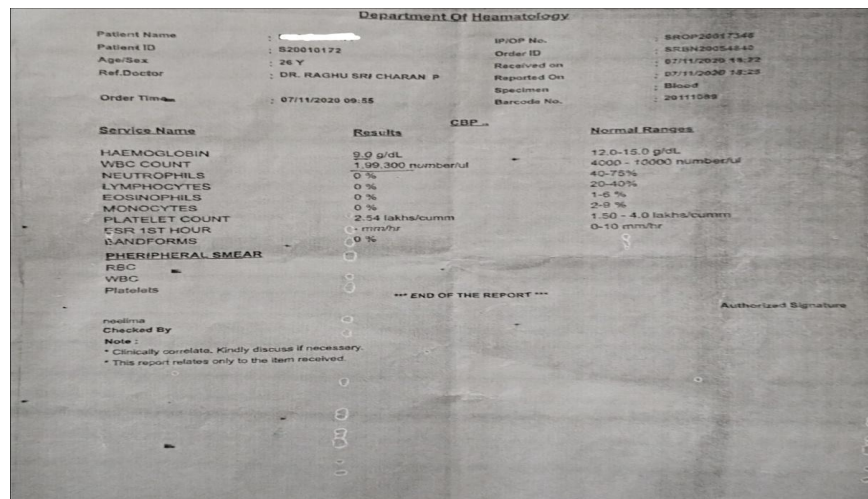


Fig. 1. Complete Blood picture report before treatment

Patient Name	[REDACTED]	Registration Date	22-02-2021 13:28
Age/Sex	25 Y/F	MR No	SSH-000220
Department	MEDICAL ONCOLOGY	Visit No	SSH-IP2100032
Doctor	Dr. SHIVA PRASAD K	Report Date	22-02-2021 15:40
Sample Date:	22-02-2021 13:49	Specimen	WHOLE BLOOD

PATHOLOGY				
Test Description	Method	Result	Units	Reference Range
CBP (COMPLETE BLOOD PICTURE)		8.8	gms/dl	13 - 18 (MALE) 12 - 14 (FEMALE)
HEAMOGLOBIN		4,500	/cmm	4,000 - 11,000
T.W.B.C		55	%	50 - 70
POLYMORPHS		33	%	25 - 40
LYMPHOCYTES		02	%	1 - 4
EOSINOPHILS		10	%	3 - 8
MONOCYTES		1.03	/cmm	1,50,000 - 4,00,000
PLATELET COUNT				

*** End of Report ***

Lab Technician

lab2
Checked By



 Dr. Shiva Prasad K
 Authorized By
 Consultant

Fig. 2. Complete Blood Picture report after a cycle of treatment

BONE MARROW ASPIRATION

Patient name: [REDACTED] Bone Marrow No: BM 16/2020
 Age/Sex: 26 yrs/ Female IP/OP NO:

CLINICAL DIAGNOSIS: CML

Bone marrow findings:
 Received 9 unstained slides
 Site: Right posterior superior iliae spine
 Cellularity: Bloody smears of marrow are hyper-cellular for age.
 M:E ratio: 10:1

Erythroid series: are markedly reduced with normoblastic maturation
Myeloid series: are severely increased in number with presence of baso shift to left & 7% blasts. Myelocyte peak are seen

Differential count of marrow:

Myeloblasts	-	7%
Promyelocytes	-	4%
Myelocytes	-	19%
Metamyelocytes	-	5%
Band forms		12%
Neutrophils		33%
Lymphocytes	-	2
Eosinophils	-	3
Monocytes	-	1

Fig. 3. Report of Bone marrow Aspiration test

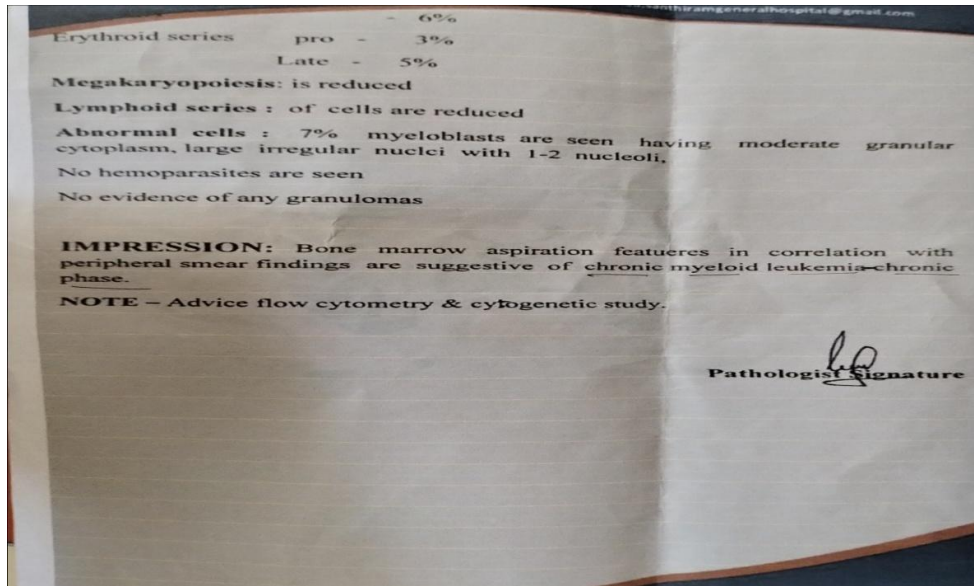


Fig. 4. Report of Bone marrow Aspiration test

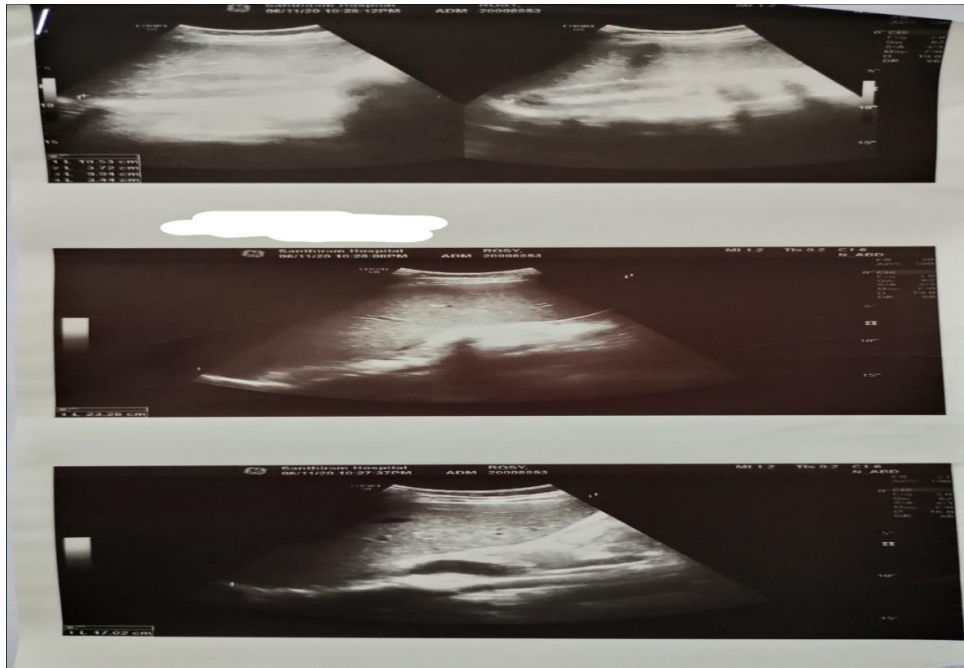


Fig. 5. Report of Ultra Sound Scan of Abdomen

3. DISCUSSION

The causation of Chronic Myeloid Leukemia was still unclear. In this case, the age factor was also uncommon. The main goal to be achieved was to control and reduce the leukocytes count. The treatment which includes Tyrosine kinase inhibitor resulted in the reduction of Leukocyte

count and has reached the normal leukocyte value in the treatment cycle itself. As shown in Fig.1, in the report of Complete Blood Picture before the treatment, the leukocyte value was dramatically increased and the values of differential count were found to be 0%. Fig. 2 depicts the Complete Blood Picture report in which the leukocyte value and Differential count

value which became normal after the first cycle of treatment. Fig. 3 and Fig. 4 illustrates the impression of Bone Marrow aspiration test which shows the severely increased myeloid series, reduced erythroid series and the abnormal cells include 7% myeloblasts having moderate granular cytoplasm, large irregular nuclei with 1-2 nucleoli. Fig. 5 shows the report of Ultrasound Scan of Abdomen in which the conditions of Hepatomegaly, Splenomegaly and Renal Parenchyma changes were depicted.

4. CONCLUSION

This case report illustrates the Chronic Myeloid Leukemia which was effectively cured by the treatment including Tyrosine Kinase Inhibitor. The Clinical features of Hepatomegaly, Splenomegaly and renal parenchymal changes associated with Chronic Myeloid Leukemia were also treated and subsided.

CONSENT

As per international standard or university standard, patients' written consent has been collected and preserved by the author(s).

ETHICAL APPROVAL

As per international standard or university standard written ethical approval has been collected and preserved by the author(s).

COMPETING INTERESTS

Authors have declared that no competing interests exist.

REFERENCES

1. Michael WN Deninger, John M Goldman, Junia V Melo, The molecular biology of chronic myeloid leukemia, Blood, The Journal of American Society of Hematology. 2000;96(10):3343-3356.
2. Gore, Jill M. MPAS, PA-Chronic Myeloid Leukemia and chronic lymphocytic leukemia, Journal of American Academy of Physician Assistants: February 2014;27(2): 45-46.
3. Savage DG, Szydlo RM, Goldman JM. Clinical features at diagnosis in 430 patients with chronic myeloid leukaemia seen at a referral centre over a 16-year period". British Journal of Haematology. 1997;96(1):111-6.
4. Michael WN Deninger, Sara Vieira, Rezzeline Mendiola, Beate Schultheis, John M Goldman-ABL tyrosine kinase activity regulates the expression of multiple genes implicated in the pathogenesis of chronic myeloid leukemia, Cancer research 2000;60(7):2049-2055.
5. Richard J Jones, Biology and treatment of chronic myeloid leukemia: Current opinion in oncology 1997;9(1),3-7.
6. Hehlmann R, Hochhaus A, Baccarani M. Chronic myeloid leukaemia". Lancet. 2007;370(9584):342-50.
7. Schoch Schnittger's Bursch C, Gerstner D, Hochhaus A, Berger Hehlmann U. Comparison of chromosome banding analysis, interphase-and hyper metaphase-FISH, qualitative and quantitative PCR for diagnosis and for follow-up in chronic myeloid Leukemia. 2002;16(1):53-59.
8. Jabbour E, Cortes JE, Giles FJ, O'Brien S, Kantarjian HM. Current and emerging treatment options in chronic myeloid leukemia". Cancer. 2007;109(11):2171-81.
9. Goldman JM, Melo JV. Chronic myeloid leukemia-advances In biology and new approaches to treatment. New Engls J Med.2003;349(15):1451-64.
10. Druker BJ, Guilhot F, O'Brien SG, Gathmann I, Kantarjian H, Gattermann N, et al. Five-year follow-up of patients receiving imatinib for chronic myeloid leukemia. The New England Journal of Medicine. 2006;355(23):2408-17.

© 2021 Umadevi et al.; This is an Open Access article distributed under the terms of the Creative Commons Attribution License (<http://creativecommons.org/licenses/by/4.0>), which permits unrestricted use, distribution, and reproduction in any medium, provided the original work is properly cited.

Peer-review history:

The peer review history for this paper can be accessed here:
<https://www.sdiarticle4.com/review-history/75732>