



Feto-placental Changes in Pregnancy Induced Hypertension

Sonti Sulochana^{a≡ω*}, Krishna Priya^{a#≡} and Sindhuja^{a†≡}

^a Department of Pathology, Saveetha Institute of Medical and Technical Sciences,
Thandalam - 602 105, Tamil Nadu, India.

Authors' contributions

This work was carried out in collaboration among all authors. Author SS designed the study, wrote the first draft of the manuscript, correction and approval of the final manuscript. Author KP wrote the protocol and wrote the draft of the manuscript. Author Sindhuja did the data collection and literature search and performed the statistical analysis. All authors read and approved the final manuscript.

Article Information

DOI: 10.9734/JPRI/2021/v33i58A34081

Open Peer Review History:

This journal follows the Advanced Open Peer Review policy. Identity of the Reviewers, Editor(s) and additional Reviewers, peer review comments, different versions of the manuscript, comments of the editors, etc are available here: <https://www.sdiarticle5.com/review-history/75834>

Original Research Article

Received 08 October 2021
Accepted 12 December 2021
Published 14 December 2021

ABSTRACT

Aims: To study if there is any difference in the foetus and placenta of pregnant women who are normotensive and those of of hypertensive patients of different severity.

Study Design: Prospective study.

Place and Duration of Study: Department of pathology, Saveetha institute of medical and technical sciences, between June 2017- June 2018.

Methodology: Pregnant women with hypertension attending obstetrics and gynecology department, Saveetha Medical College, Chennai was studied during the study period.

The study was conducted in accordance with the guidelines approved by the institutional review board of our Institution. The study population was divided into two groups namely normotensive and hypertensive patients. The hypertensive groups patients were further divided into two groups of mild (BP \geq 140/90 mm Hg with proteinuria) and severe (BP \geq 160/100 mm Hg with proteinuria). The placental specimens after expulsion were collected in 10% neutral buffered formalin solution. Informed consent was obtained in all patients and clinical data were obtained from the case notes.

[≡] Dr.;

^ω Professor;

[#] Postgraduate;

[†] Assistant Professor;

*Corresponding author: E-mail: sulochanamaster@gmail.com;

In the histopathology laboratory biopsy was taken from the insertion point of umbilical cord for light microscopy.

P-values less than 0.05 were considered statistically significant.

Data was entered in MS excel sheet and analysed using SPSS software version.

Results: The placental weight, birth weight of baby and APGAR score was decreased in PIH patients than normal pregnant women.

Conclusion: The diagnosis and treatment of PIH is very important to prevent complications in mother and baby.

Keywords: Placenta; PIH; pregnancy; hypertension; foetus.

1. INTRODUCTION

The placenta is an organ of fetal origin and it is critical to the normal growth and development of a healthy baby; it maintains a complex interface between the fetal and maternal circulations. The circulation of the placenta consists of a dynamic network of blood vessels that progresses and changes throughout the course of pregnancy, meeting the rising requirements of the embryo and foetus at each step of its development [1].

In physiological pregnancies, successful placentation includes the development of a low impedance utero-placental circulation after trophoblastic invasion and transformation of the maternal intra-myometrial portion of the spiral arterioles [2].

International society for the study of hypertension in pregnancy has classified it under four categories [3-5].

- i. Gestational hypertension
- ii. Pre eclampsia de nova or superimposed on chronic hypertension
- iii. Chronic hypertension
- iv. White coat hypertension [6].

In pregnancies complicated by pre eclampsia which is a leading cause of neonatal morbidity and mortality affecting between 3-5% of pregnancies, trophoblastic invasion of the spiral arterioles is abnormal, resulting in impaired utero-placental perfusion. This in turn results in the discharge of factors in to the maternal circulation that may be accountable for endothelial dysfunction, vasoconstriction and hypertension [7,8].

2. MATERIALS AND METHODS

Pregnant women with hypertension attending obstetrics and gynecology department, Saveetha

Medical College, Chennai during the study period June 2017 – June 2018.

The study population was divided into two groups namely normotensive and hypertensive patients. The hypertensive groups patients were further divided into two groups of mild (BP \geq 140/90 mm Hg with proteinuria) and severe (BP \geq 160/100 mm Hg with proteinuria). The placental specimens after expulsion were collected in 10% neutral buffered formalin solution. Informed consent was obtained in all patients and clinical data were obtained from the case notes. In the histopathology laboratory biopsy was taken from the insertion point of umbilical cord for light microscopy.

For test of significance, chi-square test is used. P-values less than 0.05 were considered statistically significant. Data was entered in MS excel sheet and analysed using SPSS software version.

3. RESULTS AND DISCUSSION

In our study 75 subjects were enrolled in the study, out of which 41 (55%) were hypertensive disorder or pregnancy induced hypertension (PIH) cases and 34 (45%) were normal subjects without any complications. Among the subjects with PIH, 21 (51.22%) subjects had mild PIH and 20 (48.78%) subjects had severe PIH.

In our study the age of our patients was between 20 and 34 years. In our study 32 (42.67%) patients were primiparous among the population. The mean (SD) placental weights among the normal subjects 567.94(43.05) gm were higher compared to that of PIH subjects 495.85(77.20) gm. The mean (SD) weight of the baby among normal subjects 2.94(0.41) kg were more compared to PIH cases 2.53 (0.37) kg. (Fig. 1, Tables 1,2).

The mean (SD) APGAR at 5 minutes among the normal subjects 8.00(0.00) were more compared to the PIH cases 7.68 (0.61). Also mean (SD) APGAR at 1 minute among the normal subjects 7.00(0.00) were more compared to the PIH cases 6.66(0.66). (Fig. 2, Table 3).

statistically significant. Other histopathological findings in preeclamptic patients compared to normotensive patients were increased hyalinisation and thickening of blood vessels, fibrosis, placental infarction and these findings varied with the severity of hypertension.

The mean (SD) of the syncytial knot distribution among the PIH group 7.90(3.47) was more compared to that of normal subjects 4.35(1.39). The increase in the number of syncytial knots was found to correlate with the severity of hypertension, in our study it was found that increased syncytial knots (>7 / High power field) was found more in the severe pre eclampsia group compared to mild pre eclampsia and normotensive group (Fig. 3, Table 4). The difference seen in the number of syncytial knots in placenta among the two different groups is

The figure shows the age distribution among the study population. The figure shows that age of the population lies between 20 and 34 years. In addition, majority of the subjects belong to mid-20's among the population.

The table shows that mean (SD) placental weights among the normal subjects 567.94(43.05) gm were higher compared to that of PIH subjects. This association is statistically significant.

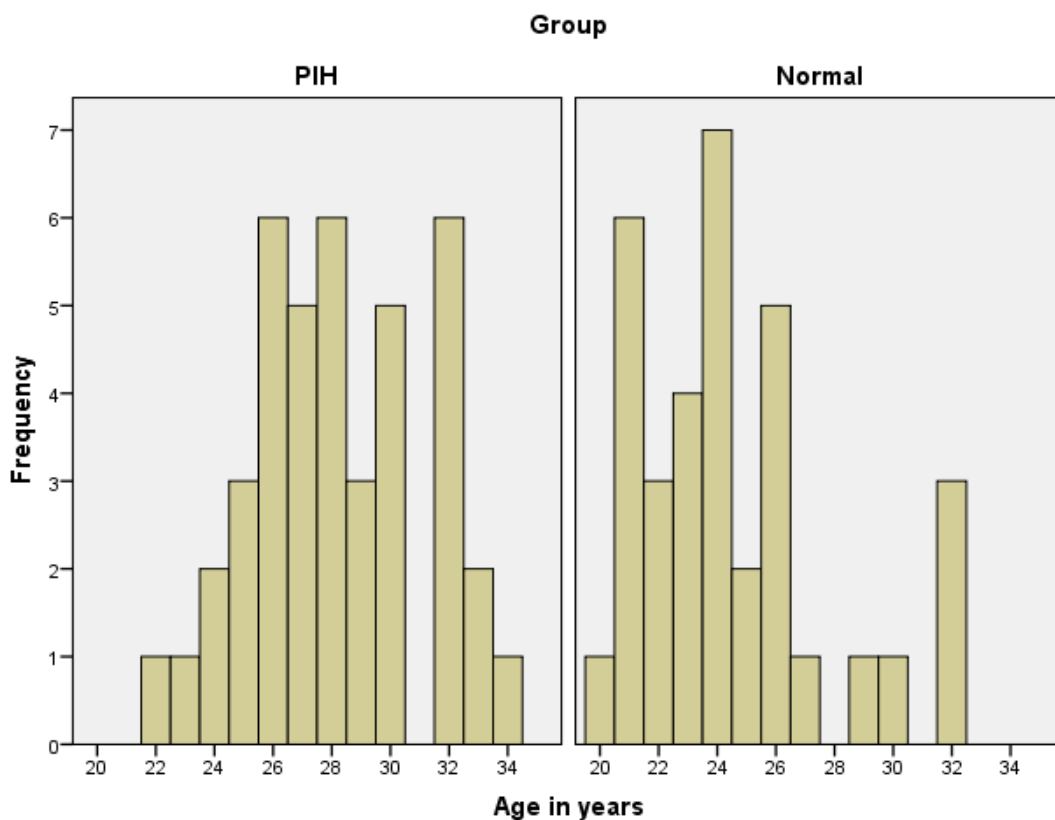


Fig. 1. Age distribution among the study population

Table 1. Placental weight among the population

	Group	N	Mean	STD. Deviation	p value by 't' Test
Placental weight	PIH	41	495.85	77.20	< 0.001
	Normal	34	567.94	43.05	

Table 2. Birth weight of the baby among the population

	Group	N	Mean	STD. Deviation	p VALUE BY 't' test
Baby weight	PIH	41	2.53	0.37	< 0.001
	Normal	33	2.94	0.41	

P value<0.05 is significant

Table 3. APGAR among the study population for 1 minute and 5 minute

	Group	N	Mean	STD. Deviation	p Value by 't' test
APGAR 1min	PIH	41	6.66	0.66	0.002
	Normal	34	7.00	0.00	
APGAR 5min	PIH	41	7.68	0.61	0.002
	Normal	34	8.00	0.00	

P value<0.05 is significant

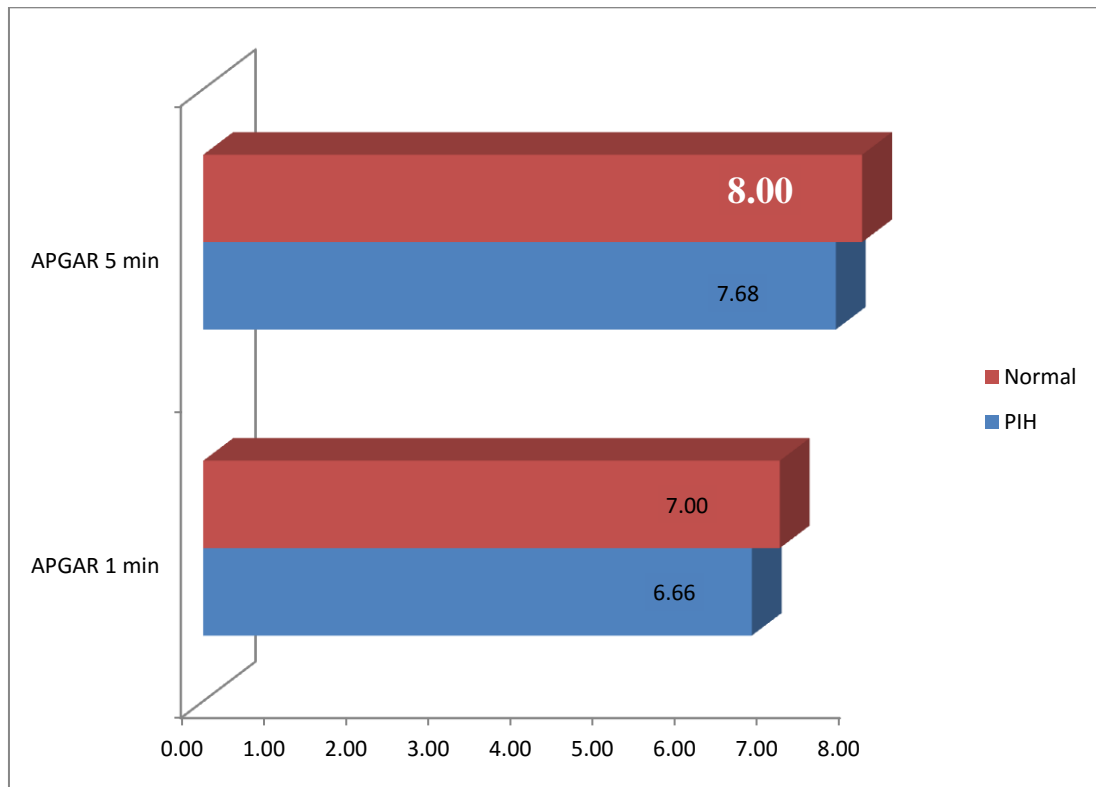


Fig. 2. APGAR among the study population for 1 minute and 5 minute

The table shows that mean (SD) weight of the baby among normal subjects 2.94(0.41) kg were more compared to PIH cases 2.53 (0.37) kg. This finding is statistically significant.

The table shows that mean (SD) APGAR at 5 minute among the normal subjects 8.00(0.00) were more compared to the PIH cases 7.68 (0.61). Also mean (SD) APGAR at 1 minute among the normal subjects of 7.00(0.00) were

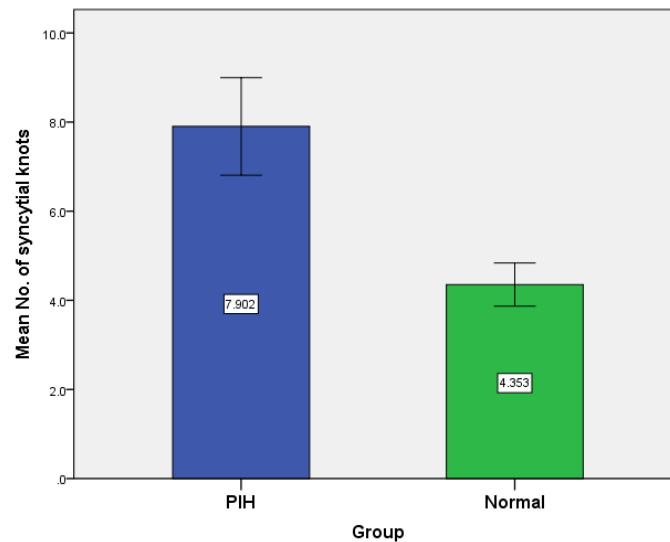
more compared to the PIH cases 6.66(0.66). This finding is statistically significant.

The table shows that mean (SD) APGAR at 5 minute among the normal subjects 8.00(0.00) were more compared to the PIH cases 7.68 (0.61). Also mean (SD) APGAR at 1 minute among the normal subjects 7.00(0.00) were more compared to the PIH cases 6.66(0.66).

Table 4. Distribution of syncytial knots among the study population

	Group	N	Mean	STD. deviation	p value by 't' test
No. of syncytial knots	PIH	41	7.90	3.47	< 0.001
	Normal	34	4.35	1.39	

P value < 0.05 is significant

**Fig. 3. Distribution of syncytial knots among the study population**

The table shows that mean (SD) of the syncytial knot distribution among the PIH group 7.90(3.47) was more compared to that of normal subjects 4.35(1.39). This finding is statistically significant.

The table shows that mean (SD) of the syncytial knot distribution among the PIH group 7.90(3.47) was more compared to that of normal subjects 4.35(1.39).

3.1 Discussion

In PIH, the main pathophysiology is the decrease in maternal uteroplacental blood flow (25). Literature support have shown that in placentas from hypertensive disorders there is hypoperfusion and increase in VEGF in placentas could be a compensatory mechanism to establish normal blood flow (56). VEGF and its receptors VEGFR1 and VEGFR2 are very crucial for the development of vasculature in the embryo (33). Carmeliet et al. (33) showed that loss of even a single VEGF allele result in embryonic death. These growth factors (VEGF) are expressed in the placenta in the early weeks and also throughout the period of gestation.

Udainie et al. showed that the placenta in PIH patients may have significant reduction in weight

and surface area and volume. Redman et al. (77) demonstrated that placental weight and size were directly proportional to the birth weight of the babies and degree of PIH. We observed similar results in our study as well.

Das Gupta et al. has shown that the histological findings in the placenta such as increased knot formation, proliferation of endothelial lining, stromal fibrosis, calcification, hyalinization of the villi and infarction are seen more often in PIH patients. These findings vary with the severity of PIH. This was similar to our findings in our study.

Placenta consists of multinucleated epithelium called syncytio- trophoblast [9-13]. Some of the nuclei are aggregated to form specialised structures called syncytial knots. Increased formation (Tenney-Parker change) is associated with placental pathology. Increase in the number of syncytial knots is associated with complicated pregnancies. Studies have shown that these knots are present in increased numbers in the villi of all term pre-eclamptic patients (74,75). This finding has been explained by the fact that there is premature aging of the placenta due to abnormal placental angiogenesis.

Fox et al. (76) has shown there is excess syncytial knot formation when there is reduced blood flow through the villi. He also demonstrated that as the pregnancy progresses the number of knots formation also increases concomitantly and suggested that it might be associated with placental maturity [14,15]. In our study, there was a significant increase in the number of knots in the placenta of the PIH group when compared with the control group. A majority of cases in the PIH group had more than 7 knots per high power field in contrast to less than 7 knots in the control group. Similar results have been shown by Narasimha et al.

4. CONCLUSION

Early diagnosis and treatment of PIH women was very important to prevent pregnancy induced complications in mother and baby before and after delivery. To save lives of mother and baby was more precious.

ACKNOWLEDGEMENTS

We thank the faculty and the supporting staff of the Department of Pathology, Saveetha Medical College for all the help rendered by them.

CONSENT

Informed consent was obtained from all patients and preserved by the author(s).

ETHICAL APPROVAL

The study was conducted in accordance with the guidelines approved by the institutional review board of our Institution.

COMPETING INTERESTS

Authors have declared that no competing interests exist.

REFERENCES

1. Ahokas RA, McKinney ET. Development and physiology of the placenta and membranes. *Glob Libr Women's Med* [Internet]. 2009 [cited 2018 Nov 30]. Available: http://www.glowm.com/index.html?p=glowm.cml/section_view&articleid=101
2. Burton GJ, Jauniaux E. Development of the human placenta and fetal heart: Synergic or independent? [Internet]. *Frontiers in Physiology*. Frontiers Media SA. 2018;9:373. [cited 2018 Nov 30]. Available: <http://www.ncbi.nlm.nih.gov/pubmed/29706899>
3. Burton GJ, Fowden AL. The placenta: A multifaceted, transient organ [Internet]. *Philosophical Transactions of the Royal Society B: Biological Sciences*. The Royal Society; 2015;370:20140066. [cited 2018 Nov 30]. Available: <http://www.ncbi.nlm.nih.gov/pubmed/25602070>
4. Ilekis JV, Tsilou E, Fisher S, Abrahams VM, Soares MJ, Cross JC, et al. Placental origins of adverse pregnancy outcomes: potential molecular targets: An Executive Workshop Summary of the Eunice Kennedy Shriver National Institute of Child Health and Human Development. In: *American Journal of Obstetrics and Gynecology* [Internet]. Mosby; 2016;S1–46. [cited 2018 Nov 30]. Available: <https://www.sciencedirect.com/science/article/pii/S0002937816004476>
5. Placental Bed Disorders: Basic Science and its Translation to Obstetrics - Google Books [Internet]. [cited 2018 Nov 28]. Available: <https://books.google.co.in/books?id=uMuQ4Q1nR4MC&pg=PA52&lpg=PA52&dq=The+placenta+an+organ+of+foetal+origin+is+critical+to+the+normal+growth+and+development+of+a+healthy+baby;+it+maintains+a+complex+interface+between+foetal+and+maternal+circulations.+The+Lyll+F.+Development+of+the+utero-placental+circulation:+The+role+of+carbon+monoxide+and+nitric+oxide+in+trophoblast+invasion+and+spiral+artery+transformation.+Microsc+Res+Tech> [Internet]. 2003 Mar 1;60(4):402–11. [cited 2018 Nov 28] Available: <http://www.ncbi.nlm.nih.gov/pubmed/12567397>
6. Lyall F. Development of the utero-placental circulation: The role of carbon monoxide and nitric oxide in trophoblast invasion and spiral artery transformation. *Microsc Res Tech* [Internet]. 2003 Mar 1;60(4):402–11. [cited 2018 Nov 28] Available: <http://www.ncbi.nlm.nih.gov/pubmed/12567397>
7. Redman CW, Sargent IL. Latest Advances in Understanding Preeclampsia. *Science* (80-) [Internet]. 2005 Jun 10;308(5728):1592–4. [cited 2018 Nov 27] Available: <http://www.ncbi.nlm.nih.gov/pubmed/15947178>
8. Walker JJ. Pre-eclampsia. *Lancet* [Internet]. 2000 Oct 7;356(9237):1260–5. [cited 2018 Nov 27] Available: <http://www.ncbi.nlm.nih.gov/pubmed/11072961>
9. Reynaud D, Sargent F, Nahed RA, Brouillet S, Benharouga M, Alfaidy N. EG-VEGF maintenance over early gestation to

- develop a pregnancy-induced hypertensive animal model. In: *Methods in Molecular Biology* [Internet]. 2018;317–24. [cited 2018 Nov 30]
Available:http://link.springer.com/10.1007/978-1-4939-7498-6_25
10. Sgambati E, Marini M, Zappoli Thyron GD, Parretti E, Mello G, Orlando C, et al. VEGF expression in the placenta from pregnancies complicated by hypertensive disorders. *BJOG An Int J Obstet Gynaecol* [Internet]. 2004 Jun;111(6):564–70. [Cited 2018 Nov 27]
Available:www.blackwellpublishing.com/bjog
 11. Murthi P, Abumaree M, Kalionis B. Analysis of homeobox gene action may reveal novel angiogenic pathways in normal placental vasculature and in clinical pregnancy disorders associated with abnormal placental angiogenesis. *Front Pharmacol* [Internet]. 2014 Jun 4;5. [cited 2018 Nov 27]
Available:<http://journal.frontiersin.org/article/10.3389/fphar.2014.00133/abstract>
 12. Redman CW, Staff AC. Preeclampsia, biomarkers, syncytiotrophoblast stress and placental capacity. *Am J Obstet Gynaecol*. 2015 Oct;213 (4 Suppl).
 13. Fogarthy NM, Fergusson-Smith AC, Burton GJ. Syncytial knots (Tenney-Parker changes) in the human placenta: Evidence of loss of transcriptional activity and oxidative damage. *Am J Pathol*. 2013 July; 183(1):144-52.
 14. Haezcell AE, Moll SJ, Jones CJ, Baker PN. Formation of syncytial knots is increased by hyperoxia, hypoxia and reactive oxygen species. *Placenta*. 2007 Apr;28 Suppl S33-40.
 15. Fox H. The significance of villous syncytial knots in the human placenta. *J Obstet Gynaecol Br Commonw*. 1965 June; 72:347-55.

© 2021 Sulochana et al.; This is an Open Access article distributed under the terms of the Creative Commons Attribution License (<http://creativecommons.org/licenses/by/4.0>), which permits unrestricted use, distribution, and reproduction in any medium, provided the original work is properly cited.

Peer-review history:

The peer review history for this paper can be accessed here:
<https://www.sdiarticle5.com/review-history/75834>