

# Rhino-orbital Fungal Invasion in Post COVID-19 Cases at a Tertiary Eye Care Centre in Hyderabad- A Cross-sectional Study

BM SHANKER VENKATESH<sup>1</sup>, P GANGA BHAVANI<sup>2</sup>, K MANJUSHA<sup>3</sup>, SANIA SULTANA<sup>4</sup>

## ABSTRACT

**Introduction:** In India, especially in Southern part of the country during the second wave of the pandemic there has been a sudden surge of rhino-orbital invasion by various fungi like *Fusarium*, *Mucor*, *Aspergillus* etc., in post Coronavirus Disease-2019 (COVID-19) patients. Several risk factors have been attributed like lowering of cell-mediated immunity by Severe Acute Respiratory Syndrome Coronavirus-2 (SARS-CoV-2), lymphopenia and associated reduction in CD4+ (Cluster of Differentiation) and CD8+ cell population, Steroid-induced hyperglycaemia, immunosuppression, and uncontrolled diabetes.

**Aim:** To detect rhino-orbital fungal conquering post COVID-19 cases.

**Materials and Methods:** This was a cross-sectional study done at a tertiary eye care centre in Hyderabad, between May to June 2021 and the study subjects were post COVID-19 patients with fungal invasion reporting to Government SD Eye Hospital and Government ENT Hospital Hyderabad, India. The patients were evaluated for associated co-morbidities, location of fungal infection, use of steroids, oxygen therapy usage and microbiologically identified

the causative fungi. Descriptive analysis was done and data was presented as numbers and percentages were calculated.

**Results:** Overall, 470 cases of post COVID-19 suspected fungal invasion cases were referred from the Ophthalmology and Ear, Nose, and Throat (ENT) Departments, of which 287 (61.06%) cases were culture positive for various fungal elements. *Fusarium* spp. was predominantly seen in 165 (57.49%) cases followed by *Aspergillus* spp. in 71 (24.74%) cases, *Mucor* was isolated in 42 (14.64%) cases and other fungi like *Candida* spp. were isolated in 5 (1.74%) cases and *Bipolaris* spp. was seen in 4 (1.39%) cases. Pre-existing Diabetes Mellitus (DM) was present in 233 (81.18%) cases, cases, corticosteroid intake for the treatment of COVID-19 was recorded in 203 (70.73%) cases and oxygen therapy was administered in 160 (55.74%) cases.

**Conclusion:** As per the evaluation especially in post COVID-19 patients there seems to be a nexus between diabetes, imprudent use of steroids, decreased immune status, inappropriate use of oxygen therapy and invasion of fungi, therefore cautious and prudent use of the steroids and oxygen among the COVID-19 treatment protocol is advised.

**Keywords:** *Aspergillus*, Coronavirus disease-2019, Diabetes mellitus, *Fusarium*, *Mucor*, Steroid therapy

## INTRODUCTION

The disastrous pandemic of the century- COVID-19 has devastated the whole universe with its morbidity and mortality. With the uncertainty in the treatment, several options have been appropriated like use of systemic steroids which remarkably increased the survival rate, but also whose widespread use had a significant toll in causing secondary bacterial or fungal infections [1]. In India, with the high prevalence of diabetes which is an alluding risk factor in the causation of fungal invasion [2,3], other risk factors include underlying co-morbidities in these patients, like, haematological malignancies (i.e., acute myeloid leukaemia) end-stage kidney disease and organ transplant recipients [4-6]. The optimal setting of raised glucose levels, low oxygen levels, high ferritin intake, decreased cell mediated immunity resulting in the failure of the first line of defence mechanisms like opsonisation, phagocytosis and mucociliary clearance and impaired second line defence mechanisms resulting in over expression of anti-inflammatory cytokines, T-helper cells [7] all these unitedly collaborated in the rise of the rhino-orbital mycosis co-infections in COVID-19 patients. Several cases of co-infection in people with COVID-19 with various fungi have recently been reported worldwide [8], but the actual incidence is unspecified and also in India [9] numerous cases of mycosis were reported during the second wave predominantly in post COVID-19 patients with diabetes and who were on steroid therapy, leading to severe complications. Mucormycosis, *Fusarium*, *Aspergillus* and *Candida* have all been reported from India in post COVID-19 patients [10]. Hence, the present study was done to detect rhino-orbital fungal conquering post COVID-19 cases.

## MATERIALS AND METHODS

This was a descriptive, cross-sectional, microbiological evaluative study of patients with Reverse Transcriptase Polymerase Chain Reaction (RT-PCR) confirmed COVID-19, who presented to Government SD Eye Hospital and also those cases referred from Government ENT Hospital Hyderabad, India, between May to June 2021 and diagnosed as rhino-orbital mycosis. This study was approved by Institutional Ethics and Research Board- Ref no: IEC/OMC/2021/Acad-49. Written informed consent was taken from each patient. Patients were diagnosed by distinctive rhino-orbital clinica symptoms like swelling of eye, orbital pain, redness of eye, etc.

**Inclusion criteria:** All post COVID-19 (RT-PCR) patients with a high index of clinical suspicion of fungal invasion of both sexes presenting to the ophthalmology and ENT clinical department of Eye Hospital and ENT Hospital, were included.

**Exclusion criteria:** All post COVID-19 (RT-PCR) patients with bacterial invasion and those who did not give consent were excluded.

**Sample size calculation:** The following formula was used for calculating the adequate sample size in prevalence study  $n = Z^2 P(1-P) / d^2$  Where 'n' is the sample size, 'Z' is the statistic corresponding to level of confidence, 'P' is expected prevalence (that can be obtained from same studies or a pilot study conducted by the researchers), and 'd' is precision (corresponding to effect size). As per the previous study and our previous laboratory observations [1], the average prevalence rate considered to be 12%.

## Study Procedure

**Specimens:** The specimens that were included for processing are:

1. Biopsy tissue samples- obtained by debridement during Diagnostic Nasal Endoscopy (DNE) and after Functional Endoscopic Sinus Surgery (FESS).
2. Deep nasal swab- which includes palatal swab and after Regurgitation On Pressure over the Lacrimal Sac (ROPLAS) swab.

**Sample processing:** Samples were collected from all those cases with fungal invasion suspicion and their biopsy material was collected under aseptic precautions in a sterile container containing normal saline. Sterile cotton swabs (HiMedia) were used to collect samples from the deep nasal, palate and for ROPLAS and processed in the Department of Microbiology, Government SD Eye Hospital. Testing of samples included direct Potassium Hydroxide (KOH) mount examination, fungal culture, and finally Lactophenol Cotton Blue (LCB) mount examination. To determine diagnosis, the direct demonstration of fungal elements in the clinical sample is necessary. The microscopic examinations of specimen in KOH (10-20% KOH) wet mount were done to detect characteristic septa, hyphae their branching etc. The size, morphology, and quantity of any fungal elements were also noted. The tissue sample were cut into small pieces and inoculated without crushing in two tubes containing Sabouraud Dextrose Agar (SDA) with antibiotics (with chloramphenicol and gentamicin, without cycloheximide) and on two tubes without antibiotics, with one tube from each set incubated at 37°C and at 22°C. The sample was also inoculated in Brain Heart Infusion (BHI) broth and blood agar and incubated at 37°C. Cultures were examined for growth daily for the first week and twice a week for the subsequent period. The fungal isolates were finally identified by conventional techniques like LPCB mount.

## STATISTICAL ANALYSIS

Descriptive analysis was done and data was presented as numbers and percentages were calculated.

## RESULTS

**Sex ratio:** Out of the 470 specimens that were processed, 287 (61.06%) specimens were fungal positive. The proportion of male patients 182 (63.41%) was higher than female patients 105 (36.59%) and the mean age of all patients was 45 years.

**Risk factors:** Various underlying risk factors and associated co-morbidities were DM, steroid use, in ardent oxygen therapy and lowered immune status state like Human Immunodeficiency Virus (HIV) [Table/Fig-1].

Risk factors	No. of cases	Percentage (%)
Diabetes	233	81.18
Steroid therapy	203	70.73
Oxygen therapy	160	55.74
HBsAg+	03	1.04
Koch's +	01	0.34
CKD	01	0.34
HIV +	01	0.34

[Table/Fig-1]: Showing risk factors and co-morbidities.

HBsAg: Hepatitis B surface antigen; CKD: Chronic kidney disease; HIV: Human immunodeficiency virus

**Clinical profile:** The [Table/Fig-2] shows distribution of 470 patients with some of the common rhino-orbital clinical symptoms like swelling of eye, orbital pain, redness and facial swelling.

**Specimens processing:** Out of the 470 specimens that were processed, 287 (61.06%) specimens were fungal positive [Table/Fig-3].

Clinical symptoms*	No. of cases	Percentage (%)
Swelling of eye	155	32.97
Orbital pain	140	29.78
Redness of eye	101	21.48
Diminished vision	64	13.61
Punctal discharge	16	3.40
Unilateral facial swelling	96	20.43
Bloody nasal discharge	44	9.36
Nasal crusting	47	10.00
Eschar on the palate	14	2.98

[Table/Fig-2]: Showing distribution of patients with rhino-orbital clinical symptoms. \*multiple symptoms

Types of specimens	Number of samples (n=470)	Positivity (n=287)	Percentage (%)
Tissue biopsy specimens after FESS and DNE.	24	10	(3.48)
Deep nasal swab (including after ROPLAS and palatal swabs).	446	277	(96.52)

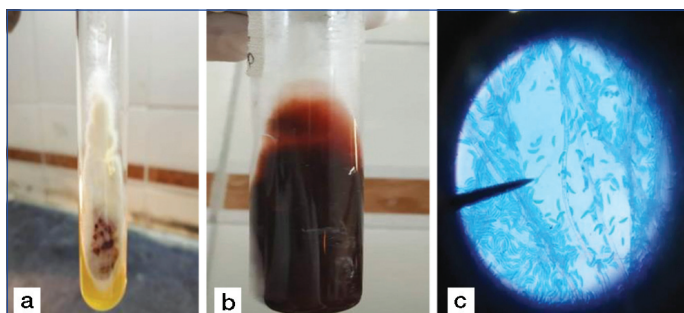
[Table/Fig-3]: Showing various specimens that were processed.

**Microbiological tests:** On combining all the microbiological investigations (KOH and culture), out of total 470 cases, there was positivity by KOH in 245 (52.12%) cases, and culture in 287 (61.06%) cases. 245 cases were positive for both KOH and culture. All isolates have been identified microbiologically by 10% KOH wet mount, culture on SDA and final diagnosis by morphological evaluation by LPCB mount.

**Microbiological profile:** Out of 287 culture isolates, *Fusarium* spp. was the most commonly identified in 165 (57.49%) cases [Table/Fig-4,5]. *Aspergillus* spp. The [Table/Fig-4,6-8] was found in 71 (24.73%) cases followed by 42 (14.63%) cases of *Mucor* [Table/Fig-4,9], 5 (1.74%) cases of *Candida* spp. [Table/Fig-4,10], 4 (1.39%) cases of *Bipolaris* spp [Table/Fig-4,11].

Fungi	Number isolated	Percentage (%)
<i>Fusarium</i> spp.	165	57.49
<i>Aspergillus</i> spp.	71	24.74
<i>Mucor</i> spp.	42	14.64
<i>Candida</i> spp.	05	1.74
<i>Bipolaris</i> spp.	04	1.39


[Table/Fig-4]: Showing fungi isolated (n=287).



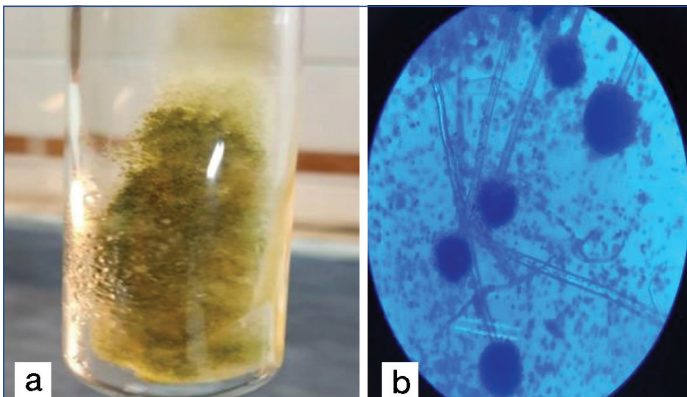
[Table/Fig-5]: Showing *Fusarium* spp. growth on SDA and microscopic appearance on LPCB; a) SDA showing white, cottony mycelial growth; b) Reverse hyaline showing dark brown colour; c) LPCB mount 40X magnification showing septate hyphae with sickle shaped macroconidia, and ellipsoidal and curved microconidia.

## DISCUSSION

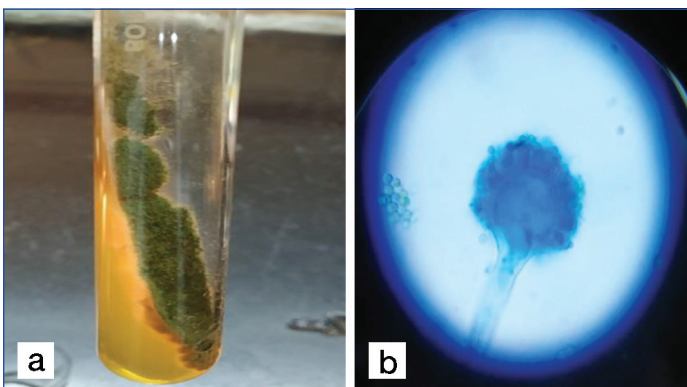
The COVID-19, caused by SARS-CoV-2, is rapidly spreading across the globe causing scads of morbidity and mortality. The aggressive feature of COVID-19 infection as cited in one of the previous study are its complications which subsist as acute




**[Table/Fig-6]:** Showing *Aspergillus niger* growth on SDA and microscopic appearance on LPCB; a) On SDA, obverse side shows woolly colonies which are yellow to white, and with time turn brown to black; b) LPCB mount 40X magnification showing conidiophores covering entire vesicle with double sterigmata with a radiate head.



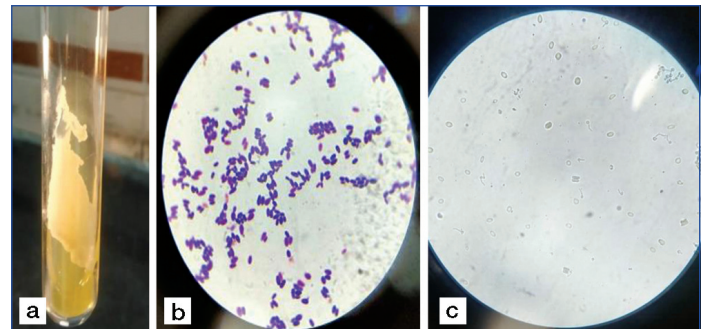
**[Table/Fig-7]:** Showing *Aspergillus flavus* growth on SDA and microscopic appearance on LPCB; a) SDA showing velvety colonies which are yellow and with time turns greenish brown; b) LPCB mount 40X magnification showing conidiophores of variable length and rough, three fourths of the vesicles are covered with single to double sterigmata.



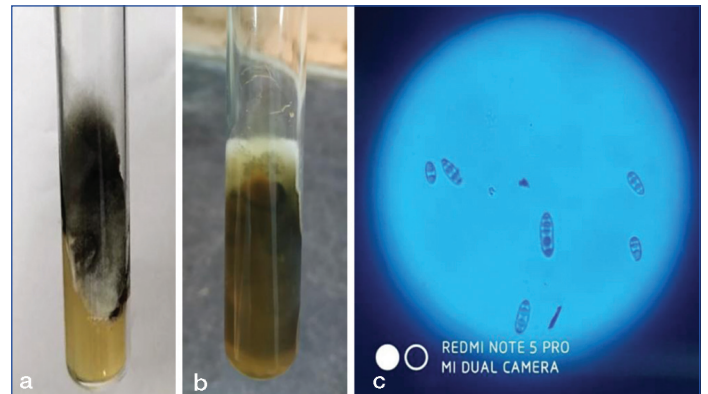
**[Table/Fig-8]:** Showing *Aspergillus fumigatus* growth on SDA and microscopic appearance on LPCB; a) SDA showing powdery colonies which are smoky green; b) LPCB mount 40X magnification showing smooth conidiophores with upper half of the vesicles covered with single sterigmata.



**[Table/Fig-9]:** Showing *Mucor* spp growth on SDA and microscopic appearance on LPCB; a) and b) SDA showing hairy appearance with White cottony colonies with tube filling growth, salt and pepper appearance; c) LPCB mount 40X magnification showing broad aseptate hyaline hyphae with wide angle branching and sporangiohore ending in sporangium.



**[Table/Fig-10]:** Showing *Candida* spp growth on SDA and microscopic appearance on LPCB; SDA showing: a) Creamy white smooth pasty colonies; b) Gram's stain 100x magnification revealed gram positive budding oval yeast cells; c) 40X magnification showing tube like germ tube projections arising from yeast cells (germ tube test positive).



**[Table/Fig-11]:** Showing *Bipolaris* spp. growth on SDA and microscopic appearance on LPCB; SDA showing: a) Obverse side shows woolly to velvety colonies which are blackish brown, and b) with time turn green to greyish black; c) LPCB mount 40X magnification showing dark septate hyphae with oblong to cylindrical, curved canoe shaped conidia with 3-5 septations.

injury (9.1%), hypoxic encephalopathy (18.2%), acute kidney injury (18.2%), shock (9.1%), and acute liver injury (9.1%) [11]. With the ongoing second wave of COVID-19 pandemic there has been a dramatic increase in the occurrence of invasive fungal co-infections observed worldwide and also in India- there has been an increase in fungal infections, predominantly rhino-orbital mycosis largely as a result of complex nexus of factors like pre-existing diseases which includes uncontrolled diabetes (especially in developing and tropical countries), use of steroid therapy, alteration in immune status as a result of COVID-19 infection causing increased cytokine levels (Interleukin-6 (IL-6), IL-10, and Tumour Necrosis Factor (TNF)- $\alpha$ ), lymphopenia (in CD4+ and CD8+ T cells), and decreased Interferon (IFN)- $\gamma$  expression in CD4+ T cells, hospitalisation in Intensive Care Units (ICU), immunocompromised states like HIV and other previous chronic diseases like Koch's, Chronic Kidney Disease (CKD) etc [9,12]. To evaluate the incidence of fungal co-infections in COVID-19 patients, authors searched various channels unfortunately we could find very few articles reporting on fungal co-infections. In a study conducted by Garg D et al., (PGIMER), Chandigarh, India the median (range) age was 57.5 (22-86) years, with male preponderance and DM was the most common predisposing condition [5]. In the present study, the mean age was 45 years and was most common in males (63.41%) as compared to females (36.59%). As previously documented, there is a strong association between poorly controlled DM and rhino-orbital invasive fungal infection as evidenced by the study done by Chakrabarti A et al., who reported an incidence of nearly 50% in patients with uncontrolled DM among the rhino-orbital cerebral fungal invasion [13]. In present study, DM was found in 233 (81.18%) patients. In a study done by White PL et al., on a strategy to diagnose COVID-19 associated invasive

respiratory distress syndrome and respiratory failure (83.3%), secondary bacterial and fungal infections (27.3%), acute cardiac

fungal disease in the Intensive Care Unit (ICU) they could find that 56.1% of the patients were on corticosteroid's therapy [14]. In the present study, also 70.73% of the patients were on steroid therapy which is therefore a significant contributory factor. As regards the oxygen therapy's role in causing fungal infection in these patients, it is controversial and search did not yield any result, but since some of the patients were on oxygen therapy in non medical voluntary establishments where proper sterilisation might not have been maintained resulting in contamination of the pipes used for oxygen, and the cylinders, therefore there may be a definite risk of fungal invasion. With regards to the studies for the secondary fungal infections in COVID-19 cases, White PL et al., screened about 135 adults with COVID-19 infection and reported an incidence of invasive fungal infections of 26.7%, aspergillosis (14.1%), *Candida* (12.6%) [14]. Chowdhary A et al., from New Delhi, India reported bloodstream *Candida* infection in 10 critically ill COVID-19 admitted patients [15]. In a Chinese study by Chen N et al., on 91 COVID-19 patients they reported five cases of fungal association (one case of *Aspergillus flavus*, one case of *Candida glabrata* and three cases of *Candida albicans* [12]. In a German study by Koehler P et al., found COVID-19 associated invasive pulmonary aspergillosis in 5 (26.3%) of 19 critically ill patient [16]. There have been several reports from India triggering a rise in COVID-19 associated rhino-orbitocerebral mucormycosis since March 2020 [17,18]. There are reports of cases of rhino-orbital mucormycosis in COVID-19 disease [7]. Sen M et al., reported six cases of COVID-19 disease with rhino-orbital mucormycosi [19]. Sarkar S et al., also reported 10 cases of clinically diagnosed orbital mucormycosis with concurrent COVID-19 infection [20].

In this study *Fusarium* spp. 165 (57.49%) was the most common fungi that have been isolated [Table/Fig-4]. The predisposing risk factors for the mycosis progression in *Fusarium* species was diverse- DM as seen in 82 (49.70%) cases, while 77 (46.67%) had a history of treatment with corticosteroids, HBsAg was positive in 3 (1.82%) cases, CKD was seen in one (0.60%) patient and one (0.60%) of the patients was HIV positive and one (0.60%) was on anti-TB treatment.

The extensive use of steroids and antibiotics as therapy against COVID-19 may lead to the development of rhino-orbital fungal diseases therefore the use of these agents should be monitored to achieve a therapeutic effect at the lowest dose and shortest durations and also the logical benefit of administering steroids in patients with COVID-19 need continuous review to avoid the increasing number of fungal invasions in these patients. Patients with DM and immunocompromised state should also be precisely monitored for fungal infection as they have an added risk of rhino-orbital fungal invasion.

### Limitation(s)

While, it is true that there are limitations of conventional diagnostic tests and not all tests are available due to lack of adequate infrastructure in intra hospital laboratories authors had tried to overcome the challenges in present setup with the available microbiological techniques and subjected all the samples first on to KOH mount and cultured in SDA and finally LPCB mount. The final diagnosis was based on the morphology in the KOH mount, cultural characteristics on SDA, and finally as per details revealed in LPCB mount.

### CONCLUSION(S)

A vigilant assess of the risk factors, identify the types of invasive mycosis, judge the strengths and limitations of diagnostic methods

and an early effective diagnosis through tissue biopsy and culture, with immediate and aggressive collaborative and individualised treatment, judicious use of antifungal drugs, surgical debridement, which all play a crucial role in reducing the high mortality and morbidity associated with mycosis.

### Acknowledgement

Authors would like to acknowledge with deep gratitude the services of all the healthcare providers around the world for their dedication in fighting the COVID-19 pandemic. Authors are thankful to Dr. V Rajalingam, Superintendent, Sarojini Devi Eye Hospital, Dr. P Modini, Head, Department of Ophthalmology, Sarojini Devi Eye Hospital, all residents and staff members of the Department of Ophthalmology and Microbiology, Sarojini Devi Eye Hospital for their care to the patients involved in the study and their help and input on the research project.

**Author contributions:** BMSV designed and planned the study, analysed the data; wrote the manuscript and supervised the whole study. PGB extracted data, contributed in the processing, under the guidance of BMSV KM and SS performed data collection and processing, and also contributed in preparing the tables and photographs under the guidance of BMSV.

### REFERENCES

- [1] Kubin CJ, McConville TH, Dietz D, Zucker J, May M, Nelson B, et al. Characterization of bacterial and fungal infections in hospitalized patients with coronavirus disease 2019 and factors associated with health care-associated infections. *Open Forum Infect Dis.* 2021;8(6):ofab201.
- [2] International Diabetes Federation. (2020). Accessed: July 7, 2020: <https://idf.org/our-network/regionsmembers/south-east-asia/members/94-india.html>.
- [3] Dallalzadeh LO, Ozzello DJ, Liu CY, Kikkawa DO, Korn BS. Secondary infection with rhino-orbital cerebral mucormycosis associated with COVID-19. *Orbit.* 2021;01-04. Doi:10.1080/01676830.2021.1903044.
- [4] Zurl C, Hoeningl M, Schulz E, Hatzl S, Gorkiewicz G, Krause R, et al. Autopsy proven pulmonary mucormycosis due to *Rhizopus microsporus* in a critically ill COVID-19 patient with underlying hematological malignancy. *J Fungi (Basel).* 2021;7(2):88.
- [5] Gang D, Muthu V, Sehgal IS, Ramachandran R, Kaur H, Bhalla A, et al. Coronavirusdisease (COVID-19) associated mucormycosis (CAM): Case report and systematic review of literature. *Mycopathologia.* 2021;186:289-98.
- [6] Khatri A, Chang KM, Berlinrut I, Wallach F. Mucormycosis after coronavirus disease 2019 infection in a heart transplant recipient- case report and review of literature. *J Mycol Med.* 2021;31:101125.
- [7] Mehta S, Pandey A. Rhino-orbital mucormycosis associated with COVID-19. *Cureus.* 2020;12:e10726.
- [8] Garg D, Liang G, Liu W. Fungal co-infections associated with global COVID-19 pandemic: A clinical and diagnostic perspective from China. *Mycopathologia* 2020;185(4):599-e606.
- [9] Dyer O. Covid-19: India sees record deaths as "black fungus" spreads fear. *BMJ.* 2021;373. <https://doi.org/10.1136/bmj.n1238>.
- [10] Singh AK, Singh R, Joshi SR, Misra A. Mucormycosis in COVID-19: A systematic review of cases reported worldwide and in India *Diabetes & Metabolic Syndrome: Clinical Research & Reviews.* 2021;15:102146.
- [11] Chen G, Wu D, Guo W, Cao Y, Huang D, Wang H. Clinical and immunologic features in severe and moderate Coronavirus disease 2019. *J Clin Invest.* 2020;2020:137244. Doi: 10.1172/JCI137244.
- [12] Chen N, Zhou M, Dong X, Qu J, Gong F, Han Y, et al. Epidemiological and clinical characteristics of 99 cases of 2019 novel coronavirus pneumonia in Wuhan, China: A descriptive study. *Lancet.* 2020;395:507-13. 10.1016/S0140-6736(20)30211-7.
- [13] Chakrabarti A, Das A, Mandal J, Shivaprakash MR, George VK, Tarai B, et al. The rising trend of invasive zygomycosis in patients with uncontrolled diabetes mellitus. *Med Mycol.* 2006;44:335.
- [14] White PL, Dhillon R, Cordey A, Hughes H, Faggian F, Soni S, et al. A national strategy to diagnose COVID-19 associated invasive fungal disease in the ICU. *Clin Infect Dis.* 2021;73(7):e1634-44. Doi: 10.1093/cid/ciaa12988.
- [15] Chowdhary A, Tarai B, Singh A, Sharma A. Multidrug-resistant *Candida auris* infections in critically ill coronavirus disease patients, India, April-July 2020. *Emerg Infect Dis.* 2020;26:11. 10.3201/eid2611.203504.
- [16] Koehler P, Cornely OA, Bottiger BW, Dusse F, Eichenauer DA, Fuchs F, et al. COVID-19 associated pulmonary aspergillosis. *Mycoses.* 2020.
- [17] Sharma S, Grover M, Bhargava S, Samdani S, Kataria T. Post coronavirus disease mucormycosis: A deadly addition to the pandemic spectrum. *J Laryngol Otol.* 2021;135(5):442-47. <https://doi.org/10.1017/S0022215121000992>.
- [18] Paul SS, Kumar R, Meena VP, Ramprasad A, Garg P, Keri VC, et al. Clinical characteristics and outcomes of 16 cases with COVID-19 and mucormycosis: Experience from a tertiary care center in India and review of literature. 2021. <https://doi.org/10.21203/rs.3.rs-533347/v1>. Accessed June 21, 2021.

- [19] Sen M, Lahane S, Lahane TP, Parekh R, Honavar SG. Mucorin a viral land: A tale of two pathogens. Indian J Ophthalmol. 2021;69:244-52.
- [20] Sarkar S, Gokhale T, Choudhury SS, Deb AK. COVID-19 and orbital mucormycosis. Indian J Ophthalmol. 2021;69:1002-04.

**PARTICULARS OF CONTRIBUTORS:**

1. Professor, Department of Microbiology, Sarojini Devi Eye Hospital/Osmania Medical College, Hyderabad, Telangana, India.
2. Assistant Professor, Department of Microbiology, Sarojini Devi Eye Hospital/Osmania Medical College, Hyderabad, Telangana, India.
3. Postgraduate Trainee, Department of Microbiology, Sarojini Devi Eye Hospital/Osmania Medical College, Hyderabad, Telangana, India.
4. Postgraduate Trainee, Department of Microbiology, Sarojini Devi Eye Hospital/Osmania Medical College, Hyderabad, Telangana, India.

**NAME, ADDRESS, E-MAIL ID OF THE CORRESPONDING AUTHOR:**

Dr. BM Shanker Venkatesh,  
Flat No. B305, Sai Pragati Pride Apt., SS Nagar, Street No. 8, Habsiguda,  
Hyderabad-500007, Telangana, India.  
E-mail: Shanker.bunde@gmail.com

**PLAGIARISM CHECKING METHODS:** [\[Jain H et al.\]](#)

- Plagiarism X-checker: Sep 02, 2021
- Manual Googling: Dec 08, 2021
- iThenticate Software: Dec 31, 2021 (19%)

**ETYMOLOGY:** Author Origin**AUTHOR DECLARATION:**

- Financial or Other Competing Interests: None
- Was Ethics Committee Approval obtained for this study? Yes
- Was informed consent obtained from the subjects involved in the study? Yes
- For any images presented appropriate consent has been obtained from the subjects. NA

Date of Submission: **Sep 01, 2021**Date of Peer Review: **Oct 22, 2021**Date of Acceptance: **Jan 03, 2022**Date of Publishing: **Feb 01, 2022**