



An Unusual Case of Extra-oral Pyogenic Granuloma

Rohit Mishra^{1*}, K. T. Chandrashekar¹, Vandana Dubey Tripathi¹,
Richa Agrawal¹ and Neha Bhasin²

¹Department of Periodontics, Hitkarini Dental College and Hospital, Madhya Pradesh Medical Science University, India.

²Department of Oral Medicine and Radiology, Hitkarini Dental College and Hospital, Madhya Pradesh Medical Science University, India.

Authors' contributions

This work was carried out in collaboration between all authors. Author RM did the surgical excision of the lesion. Authors RM, KTC, VDT, RA and NB helped in formulation of the manuscript. Author NB diagnosed the case. Author RM helped in reviewing and editing the manuscript. All the authors helped in finalizing the manuscript.

Article Information

DOI: 10.9734/BJMMR/2017/32972

Editor(s):

(1) Karl Kingsley, Biomedical Sciences and Director of Student Research University of Nevada, Las Vegas - School of Dental Medicine, USA.

Reviewers:

- (1) Babatunde O. Bamgbose, Bayero University, Kano, Nigeria.
(2) Vinay Marla, Kathmandu University School of Medical Sciences, Dhulikhel, Nepal.
(3) Kuo Yuan, National Cheng Kung University, Taiwan.
Complete Peer review History: <http://www.sciencedomain.org/review-history/18668>

Case Report

Received 25th March 2017
Accepted 4th April 2017
Published 17th April 2017

ABSTRACT

Pyogenic granuloma is a moderately common, benign mucocutaneous lesion. It is a tumor-like proliferation to a non specific infection. It is non-neoplastic in nature and presents in different clinical and histological forms. In appearance, they are typically solitary and vascular usually seen in the oral cavity. It is an oral disease which appears in the mouth as an overgrowth of tissue in response to irritation, physical trauma or hormonal factors. The name for pyogenic granuloma is misnomer because of the fact that it is not a true granuloma. Skin of the face and neck, upper and lower extremities, and mucous membranes of nose and eyelids are common areas for extraoral involvement. The clinical diagnosis of extraoral variant of this lesion being an uncommon occurrence can be quite challenging and misleading as they sometimes may mimic more serious lesions. The purpose of this article is to report an unusual case of pyogenic granuloma occurring on lower lip.

*Corresponding author: E-mail: drohitmishra7@gmail.com;

Keywords: Extraoral; lower lip; pyogenic granuloma; rare variant.

1. INTRODUCTION

Pyogenic granuloma is a relatively common benign mucocutaneous lesion seen in oral cavity & peripheral extremities. It was first described in 1897. It is a special type of inflammatory hyperplasia which often arises in 2nd or 3rd trimester of pregnancy and hence is termed as "Pregnancy Tumor". Although this lesion is reported in all age groups, the peak incidence is reported in third decade of life affecting women more often than men [1].

Over the years various authors have suggested other names such as granuloma gravidarum, pregnancy tumor, crocker and Hartzell's disease, vascular epulis, benign vascular tumor, hemangiomatosis granuloma, epulis teleangiectaticum granulomatosa, and lobular capillary hemangioma [2,3]. Cawson et al. [4] suggested that since the blood vessels are so numerous in oral pyogenic granuloma, alternative term for pyogenic granuloma is granuloma telangiectaticum. There are two kinds of pyogenic granuloma namely lobular capillary hemangioma (LCH type) and non LCH type, which differs in their histological features.

Clinically pyogenic granuloma is a smooth or lobulated exophytic lesion, manifesting as solitary, small, red erythematous papule on a pedunculated or sessile base, varying in diameter from few millimeters to centimeters. The surface is ulcerated and friable which may be covered by a yellow fibrinous membrane with color ranging from pink to purple depending upon the age of the lesion [5,6].

2. CASE REPORT

A 32-year-old male patient reported to the Department of Periodontics, Hitkarini Dental College & Hospital Jabalpur with the chief complaint of growth on left side of lower lip since 4 months. The growth was asymptomatic except for the esthetic discomfort. The growth was initially small in size and gradually increased to present condition. Past medical history was of no relevance and general physical status was good with no other skin lesions. Extraoral examination revealed solitary exophytic growth on lower lip (adjacent to left commissure), irregular in shape, measuring approximately 4 X 1.5 cm in size. Surface of the growth appeared rough and lobulated with brownish black color (Fig. 1). On palpation, it was firm in consistency,

compressible, non tender, non reducible, non bleeding and non pulsatile in nature. A provisional diagnosis of hemangioma was made and a differential diagnosis of traumatic fibroma was considered. Routine hemogram was advised and the resultant values were under normal physiological limits.

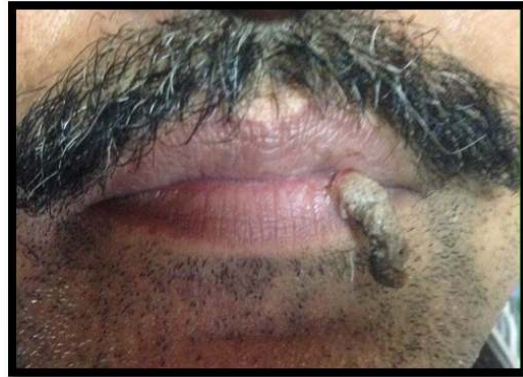

Fig. 1. Preoperative view

Surgical excision of the lesion was advised and written informed consent was taken. Phase I therapy was completed and the patient was recalled after 1 week. The case was prepared for surgery on the basis of the clinical and hematologic evaluation. Excision of lesion was done under aseptic conditions with soft tissue diode laser. The lesion was excised by Soft-tissue Diode Laser (manufactured by Picasso: wavelength 810 nm (\pm 10), output energy 2.5W, and input power 300 VA. We used 810-nm wavelength and 7 W power), in interrupted pulse mode. Topical local anesthesia spray was used. It took 4-5 min to completely excise the mass. The diode laser provided an optimum combination of clean cutting of the tissue and haemostasis (Fig. 2). Routine analgesics were prescribed. The excised tissue was sent to the Department of Oral Pathology for histopathologic examination. Follow up after a week and subsequent 1 month, 3 months and 6 months revealed complete uneventful healing (Fig. 3).

Histopathological examination with Haematoxylin and Eosin stained section [10X] revealed atrophic parakeratinized stratified squamous epithelium covering fibrocellular connective tissue stroma, numerous dilated and engorged capillaries, plump endothelial cells and chronic inflammatory cells. A final diagnosis of pyogenic granuloma was given (Fig. 4).

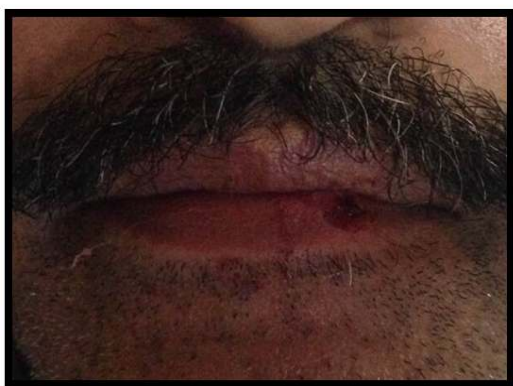

Fig. 2. Immediate postoperative view

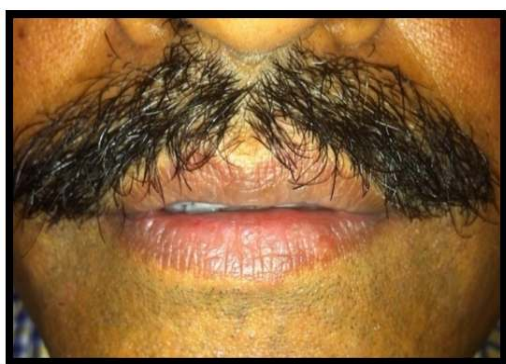

Fig. 3. Postoperative view after 6 months

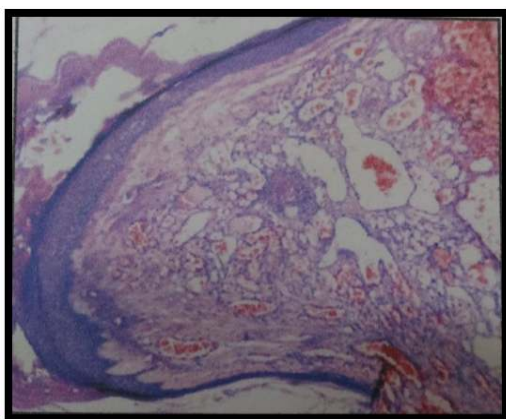


Fig. 4. Histopathological finding

3. DISCUSSION

Pyogenic granuloma is a kind of inflammatory hyperplasia. The term inflammatory hyperplasia is used to describe a large range of nodular growths of the oral mucosa that histologically represents inflamed fibrous and granulation tissue [7,8]. Oral pyogenic granuloma is the most

common gingival tumor, accounting for 75% of all the cases. In the oral cavity, pyogenic granulomas show a striking predilection for the gingiva, with interdental papillae being the most common site in 70% of the cases. The lips, tongue, and buccal mucosa are the next most common site. They are more common in the maxillary anterior area than any other areas in the mouth. Gingival irritation and inflammation resulting from poor oral hygiene, dental plaque and calculus or over hanging margins restorations may be precipitating factors in many cases [9]. There is a consensus that the region of higher occurrence of intraoral pyogenic granuloma is the gum, probably because the area is the most subject to the action of traumatic and/or irritating agents [10]. Pyogenic granulomas of head and neck are uncommonly seen in areas of frequent trauma such as tongue and palate and rarely lower lip [9].

Although pyogenic granuloma can be diagnosed clinically with considerable accuracy, radiographic and histopathological investigations aid in confirming the diagnosis and treatment. Radiographs are advised to rule out bony destructions suggestive of malignancies for identification of a foreign body. Differential diagnosis of pyogenic granuloma includes peripheral giant cell granuloma, peripheral ossifying fibroma, metastatic cancer, hemangioma, basillary angiomatosis, angiosarcoma and non Hodgkins lymphoma [9].

Although the lips are common areas of occurrence of trauma, some authors consider that pyogenic granuloma lesions are unusual in this location. Gonçalves et al. reported a case of involvement of the upper lip in a 12-year-old female patient. In another unusual case, described by Vasconcelos et al. [11] lower lip was affected in a 53-year-old patient. The clinical diagnosis of extraoral variant of this lesion being an uncommon occurrence can be quite challenging and misleading as they sometimes may mimic more serious lesions. The present case report is unusual because of the site of involvement and its clinical appearance which appears quite masquerading.

Management of pyogenic granuloma depends on the severity of symptoms. If the lesion is small, painless and free of bleeding, clinical observation and follow up are advised. Other treatment modalities include laser surgery, electrodesiccation. Injection of absolute ethanol, sodium tetradecyl sulfate (sclerotherapy) and

corticosteroids have also been tried with successful results in cases with recurrent lesions. Recurrence occurs in upto 16% of the lesions, which might be due to incomplete excision, failure to remove etiologic factors, or due to reinjury to the area, making follow up necessary [9]. The advantages of surgical excision with laser over other conventional technique are that it provides a blood less field for excision along with healing with primary intention without sutures.

4. CONCLUSION

In conclusion, extraoral pyogenic granuloma can present with unusual features. They can have masquerading appearances when present at such unusual locations with unusual features. In such clinical situations, the treatment plan should be made accordingly wherein surgical excision is the treatment of choice for the same.

CONSENT

All authors declare that 'written informed consent was obtained from the patient (or other approved parties) for publication of this case report and accompanying images'.

ETHICAL APPROVAL

It is not applicable.

COMPETING INTERESTS

Authors have declared that no competing interests exist.

REFERENCES

1. Bhaskar SN, Jacoway JR. Pyogenic granuloma – clinical features, incidence, histology, and result of treatment: Report of 242 cases. J Oral Surg. 1966;24:391-8.
2. Graham RM. Pyogenic granuloma: An unusual presentation. Dent Update. 1996; 26(1):240-41.
3. Bjork K, Hoede N, Korting GW, Burgdorf WHC, Young SK. Disease of the oral mucosa and the lips. Philadelphia: WB Saunders. 1996;229-30.
4. Cawson RA, Binnie WH, Speight PM, Barrett AW, Wright JM Lucas Pathology of tumors of oral tissues. 5th ed. Missouri: Mosby. 1998;252-4.
5. Neville BW, Damm DD, Allen CM, Bouquot JE. Oral and maxillofacial pathology. 2nd ed. W.B. Saunders. 2004;437-95.
6. Ragezi JA, Sciubba, James J, Jordan Richors CK. Oral pathology, clinical pathologic correlation. Fourth. Sanders Company. 2003;115-76.
7. Eversole LR. Clinical outline of oral pathology: Diagnosis and treatment. 3rd Ed., Bc Decker, Hamilton. 2002;113-4.
8. Greenberg MS, Glick M. Burket's oral medicine: Diagnosis and treatment. 10th Ed., BC Decker, Hamilton. 2003: 141-2.
9. Kurian B, Sasirekha, Ebenezer. Pyogenic granuloma- A case report and review. International Journal of Dental Sciences and Research. 2014;2(3):66-8.
10. Jafarzadeh H, Sanatkhanani M, Mohtasham N. Oral pyogenic granuloma: A review. J Oral Sci. 2006;48(4):167-75.
11. Vasconcelos MG, Vasconcelos RG, Mafra RP, Queiroz LMG. Pyogenic granuloma on the lower lip: An unusual location. Stomatos. 2012;18(35):34-8.

© 2017 Mishra et al.; This is an Open Access article distributed under the terms of the Creative Commons Attribution License (<http://creativecommons.org/licenses/by/4.0>), which permits unrestricted use, distribution, and reproduction in any medium, provided the original work is properly cited.

Peer-review history:

The peer review history for this paper can be accessed here:
<http://sciencedomain.org/review-history/18668>