



Extremity Amputations in Children from Complications of Traditional Bone Setters' Care Seen in a Tertiary Hospital in Port Harcourt, Nigeria

T. E. Diamond¹, S. E. B. Ibeanusi^{1*}, R. C. Echem¹ and C. C. Aniebo¹

¹Department of Orthopaedic Surgery, University of Port Harcourt Teaching Hospital, Port Harcourt, Nigeria.

Authors' contributions

This work was carried out in collaboration between all authors. Author TED designed the study, the protocol, managed the literature searches and wrote the first draft of the manuscript. Author SEBI contributed in the design of the study, reviewed the protocol, managed the literature searches and wrote the 2nd and final drafts of the manuscript. Authors RCE and CCA helped in data collection and managed the analyses of the study. All authors read and approved the final manuscript.

Article Information

DOI: 10.9734/AIR/2018/41744

Editor(s):

(1) Jinyong Peng, Professor, College of Pharmacy, Dalian Medical University, Dalian, China.

Reviewers:

(1) A. Papazafiropoulou, Tzaneio General Hospital of Piraeus, Greece.

(2) Ali Al Kaissi, Orthopedic Hospital of Speising, Austria.

(3) Duncan D. Mugala, Copperbelt University, Zambia.

(4) Vijaya Krishnan, MGM College of Physiotherapy, India.

Complete Peer review History: <http://www.sciencedomain.org/review-history/24628>

Received 9th March 2018

Accepted 11th May 2018

Published 17th May 2018

Original Research Article

ABSTRACT

Background: The ancient practice of traditional bone setting dates back many centuries. In the developing world, the traditional bone setters are still patronized despite numerous limb and life-threatening complications that result from their treatment of limb injuries. Limb amputation in children resulting from bonesetter's gangrene is a common and a disturbing complication.

Aim: To present six consecutive cases of extremity amputations in children resulting from bonesetters' gangrene.

Results: Six consecutive extremity amputations resulting from bonesetters' gangrene were done at the study site from April 2013 to March 2016, constituting 8% of all limb amputations and 73% of all extremity amputations done in children within the same period. Five of the patients were males while one was female. Ages ranged from 18 months to 17 years with a mean age of 10.2±13.3 years. All amputations involved the upper limb. All patients visited the traditional Bone setters (TBS) with five

*Corresponding author: E-mail: Sydney_ibe@hotmail.com;

of patients 'admitted' in the Bone Setter's place for more than two weeks. The treatment method was similar in all patients and involved the use a tight splint localized to the fracture site and intermittent massage using a local ointment. All patients had satisfactory wound healing and were discharged home not later than the 14th-day post surgery.

Conclusion: Limb gangrene is one of the most regrettable complications following Traditional Bonesetters treatment of extremity injuries. With the poor rehabilitative function of amputated limbs and the high cost of the functional prosthesis in the sub-region, urgent steps are needed to prevent such complications in the sub-region.

Keywords: Amputation; bonesetter's gangrene; extremity amputation; children.

1. INTRODUCTION

1.1 Background

A traditional bone setter (TBS) is a person recognized by the community where he lives as competent to set bones using traditional appliances [1]. The traditional bone setting is an ancient practice dating back many centuries especially in countries like Egypt, China and a few others and is regarded as a specialized aspect of traditional medicine with interest in orthopaedics [2-4]. In the developing world, the traditional bone setter (TBS) still receives high patronage despite the numerous limb and life-threatening complications resulting from his treatment of limb injuries [5]. This level of patronage may be fuelled by the strong faith in traditional healing methods easy accessibility to rural dwellers (constituting a significant fraction of the population in most developing nations) [6], presumed lower cost compared to orthodox orthopaedic care, [7,8] fear of amputation in conventional centres and service interruptions (from industrial strike actions) in hospitals [7,9]. The hallmark of TBS complications of care on the injured limb is neurovascular compromise from tight application of splints at fracture sites leading to distal limb gangrene aptly called bone setters gangrene [10-12].

Most hospital-based studies in sub-Saharan Africa report regrettably high rates of extremity amputations in children from bonesetters' gangrene [13,14]. Children's inability to contribute to their own health care decisions when injured, their complete financial dependence of parents/ guardians and the strong societal faith on TBS practice irrespective of educational and economic status, may have contributed to the high rate.

AIM: To present six consecutive cases of extremity amputations in children resulting from bonesetters' gangrene.

2. METHODS

Appropriate Ethical approval according to Helsinki Declaration 1977 was obtained from the Hospital Authority. Information from all the cases of children presenting to the hospital with gangrene after a visit to traditional bone setter was collected after securing informed consent from their parents or legal surrogate. Information on the cause of injury, reasons for the visit to traditional bone setter, treatment received at the bone setter home, and reasons for seeking discharge from the traditional bone setters' home were collected. Data were analysed and presented

3. RESULTS

Six consecutive extremity amputations resulting from bonesetters' gangrene were done at the study site from April 2013 to March 2016, constituting 8% of all limb amputations and 73% of all extremity amputations done in children within the same period. 5 of the patients were males while one was female.

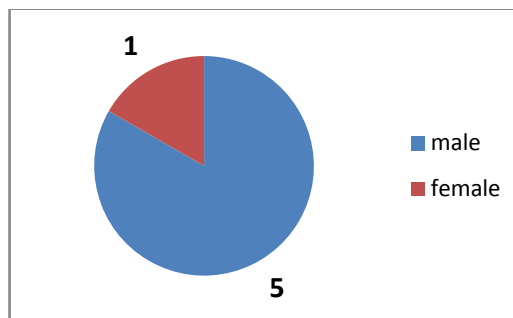


Fig. 1. Gender distribution

Age of the patients ranged from 18months to 17 years with a mean age of 10.2±13.3 years. All amputations involved the upper limb, with a left to right ratio of 1:2. The initial injury in 3 cases (50%) was closed proximal humeral fracture

while one case (16.7%) was a closed supracondylar fracture. Closed humeral shaft fractures were responsible for 2 of the cases (33.3%).

Table1. Distribution of primary injuries

Primary injury	Nos.	Percentage
Closed proximal humeral fracture	3	50%
Closed humeral shaft fracture	2	33.3%
Closed supracondylar fracture	1	16.7%
Total	6	100%

All the patients visited traditional Bone setters (TBS) with five of the patients 'admitted' in the Bone Setter's place for more than two weeks. The treatment method was similar in all patients. It involved an initial application of a tight splint localized to the fracture site for 48 to 72 hours with the subsequent intermittent release for massage using a local ointment. Two patients, however, reported that incisions were also made at the fracture site (using unsterile instruments) at the time of 'tourniquet-splint' release followed by application of locally-made ointment to the wound. The onset of severe deep-seated pain that worsened with passive motions across the wrist was noticed by all patients earlier than 24 hours into the commencement of TBS treatment. All the six children also raised concerns about changes in the appearance and function of their limbs but were repeatedly reassured by both parent/guardian and the Traditional Bone Setters.

Hospital presentation was necessitated by apparent signs of limb gangrene in 4 of the 6 (66.7%) of cases, auto-amputation of the limb in one case (16.7%) and manifestations of septic shock in one case (16.7%).

All six patients had upper limb amputations less than 24 hours into hospital presentation for wet gangrene of the involved limb (from the fracture to the rest of the distal limb) or refashioning of the stump of the already amputated limb. Five of the cases (83.3%) were trans-humeral amputations while one case (16.7%) was at a level about 5cm above the elbow.

The mean duration for delayed primary wound closure was 14.6±2.4 days. All patients had satisfactory wound healing and were discharged home not later than the 14 days post surgery.

4. DISCUSSION

Limb gangrene is one of the most regrettable complications following Traditional Bonesetters treatment of extremity injuries, especially in children. The incidence of this complication is also high from most hospital-based reports [15,16].

Nwandinigwe et al. [15] in Enugu showed that bonesetters gangrene was responsible for 44% (n=59/134) of amputations at the National Orthopaedic Hospital Enugu within a five year period while Garba et al. [16] in a ten-year hospital-based study in Zaria showed 39.6% of amputations from TBS gangrene. Bonesetters gangrene contributed to 8% of all amputations

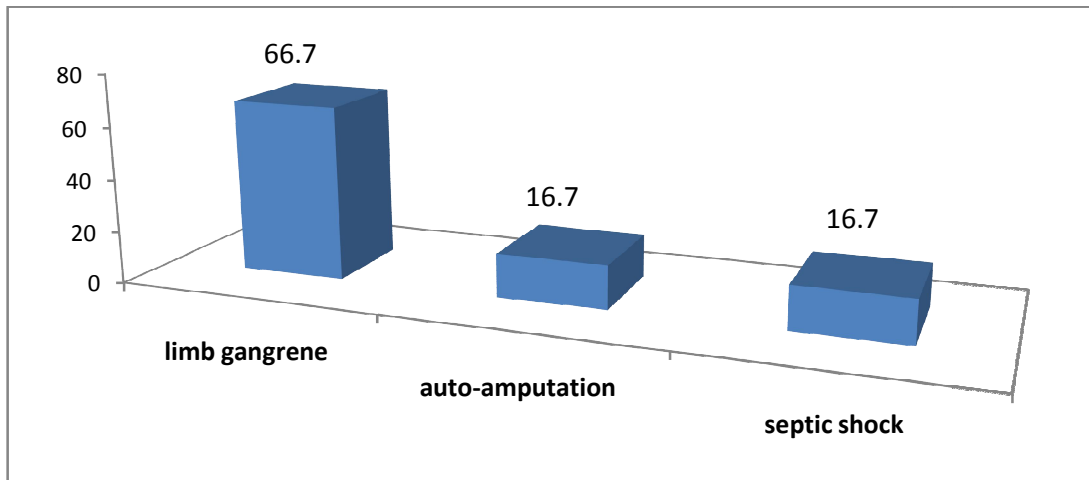


Fig. 2. Reasons for presentation to hospital

and 73% of paediatric limb amputations within a three year period in this study. This was Similar to findings by Umaru et al. [17] in Maiduguri (31.7%). Onuminya et al. [18] in a multi-centre study however showed that bonesetters gangrene was responsible for 60% of 100 amputations within a 10-year period. The higher figure (73%) in this study may stem from the age restriction on the study population especially as acquired amputation from trauma is not very common in children as compared to adults [19] partly because high energy trauma is also not as common in children as in adults. Acquired amputation in children more often results from treatment of malignant tumors of the extremity. Congenital amputations are commoner in children. Despite the fact that pediatric limb amputations are rare and unique, they account for a disproportionately significant component of the morbidity associated with trauma [20]. It has been reported that children who had amputations as a result of malignancy adapted better to disability in comparison with those that had amputations due to trauma [21].

Avoidance as coping styles is a significant predictor of psychosocial adaptation for children amputee. Such avoidance has been strongly associated with emotional anguish and poor adjustment [22,23]. Presence of significant depressive symptoms in up to 28.3% of patients and significant anxiety symptoms in about 35.5% of paediatric patients with limb amputations, as measured by the Hospital Anxiety and Depression Scale, Depression subscale (HADS-D) have been reported [22,24]. Post-traumatic Stress Disorder (PTSD) is a common psychiatric disorder experienced after such traumatic events and can be observed in not only the pediatric amputee, the immediate family as well as in their primary caretaker of the amputee. This psychological disorder ultimately influences the overall rehabilitation of the child [25].

Children are vulnerable to such complications from TBS treatment for reasons that they are prone to road traffic crash-related injuries especially in environments where road safety regulations are either non-existent or poorly upheld. Street hawking and street begging for alms especially by the under-aged is still rife in the environment. Such practise presents a particular question on child safety legislation and enforcement in the system. Seasonal Injury patterns resulting from falls from mango trees

and other fruit bearing trees are also known in the environment [26,27].

Secondly, children rely on parents and guardians to take decisions on where to receive care for injured limbs and when to move from one point of care to another. Solagberu [28] has aptly termed this "the external locus of control in decision making" which he believes overwhelmingly suppresses the patient's innate desire on where to seek treatment; "the internal locus of control in decision making". Lastly, since children are seen as not capable of contributing to their health care, their complaints and opinions may not be considered even in the course of treatment. For instance, all six children in the study raised concerns about changes in the appearance and function of their limbs which were repeatedly ignored by both parent/guardian and the Traditional Bone Setters.

With the poor rehabilitative function of amputated limbs in the sub-region, the impact of preventable limb amputations in children in the sub-region is difficult to estimate. Onuminya et al. [18] noted that 73.9% of 96 amputees who became the crutch or wheelchair ambulators and were viewed with suspicion from members of their societies. For children, the burden is beyond societal suspicion. Limb amputations especially those involving the lower limb will increase the energy requirements needed to walk from home to school particularly in regions with fewer schools and longer distance between homes and schools. With limited availability of affordable, safe mobility, this will contribute to school drop-out rates and further reduce literacy levels in the society. Also, these children will find it difficult to participate in recreational and sporting activities needed for the child's complete psycho-social development.

Furthermore, limb amputations limit the employment options available to the child upon graduation from school. A child with the desire to pursue a career in a particular profession may be forced to squander his dreams on the altar of a preventable amputation. This loss of future ambition is even more worrisome as there is little or no social insurance or welfare scheme for the disabled in the region [29].

With the poor rehabilitative function of amputated limbs in our sub-region, the impact of preventable limb amputations in our sub-region is difficult to estimate. The need to periodically

change prosthesis in growing children even present more challenge for most of the children and their parents especially where there are not readily available functional prosthesis in the region 29.

More worrisome is that these amputations involved the upper extremity. Upper extremity prostheses at the moment remain more complicated and more problematic than those of lower extremity. The prosthetic replacement of upper-limb function can be a daunting task for the rehabilitation team. Part of the reason for this is that a substantially more considerable amount of neurological area within the human brain is dedicated to the motor and sensory functions of the upper limb than the lower limb³⁰. This complexity of children prosthesis has to be considered in the design and fabrication of a good prosthesis to reduce the pscho-functional morbidity from amputations especially acquired traumatic amputations. An overall 90 percent upper-limb impairment and 54 percent whole person impairment exists when a person loses his or her fingers and thumb [31].

An important and significant problem with traumatic pediatric amputations is also the osseous overgrowth which can lead to difficulty with prosthesis fitting, pressure ulcers and skin perforation. Numerous surgical revisions, therefore, may be required to avoid such consequences of osseous overgrowth [32]. Such revisions may not be readily affordable to the parents of the child amputee as and when due thus leading to significant secondary complications.

Lastly, in societies with deeply held religious and cultural beliefs, these patients may be termed "structurally incomplete" and may be subjected to intense discrimination bordering on inheritance rights, marriage options, choice of friends and playmates and sometimes place of burial on demise. The authors strongly appeal to health care planners in developing countries to look into the morbidity caused by unsupervised treatment of limb injuries by traditional bone setters. Bickler and Sanno-Duanda in the Gambia estimate that 7% of children living in urban areas of sub-Saharan Africa will require care for fractures by the time they reach 15years [33]. The lack of primary trauma care for these children will place a considerable number at significant risk of morbidities and sometimes mortalities from

inadequate medical treatment including those from TBS. Cases of amputations arising from traditional Bone setter treatment for simple soft tissue injuries without fracture had been recorded mainly as some TBS do not utilize radiographs and insists that their clients do not do any radiographic studies [34]. Also, with the majority of Injuries and fractures in rural Africa being treated by Traditional bone setters, the authors believe that African countries should start considering providing basic training to the TBS on care for fractured limbs. This training should focus on proper orientation on the TBSs capabilities, education preferable with (pictorial evidence) on the potential dangers of applying a splint too tightly, identification of a threatened limb and quick referral of such patients to orthodox health centres.

5. CONCLUSION

The menace of Traditional Bonesetters resulting in amputations in children in the region is real. Such complications contribute to the significant disability Adjusted Life lost to injuries in the region especially when they occur in children who are meant to live with such avoidable deformity and disability for life. Urgent steps are required to stem these catastrophic consequences.

COMPETING INTERESTS

Authors have declared that no competing interests exist.

REFERENCES

1. Onuminya JE. The role of traditional bone setters in primary fracture care in Nigeria. *S Afr Med J*. 2004;94(8):652–658.
2. Omonzejele FP. Current ethical and other problem in the practice of Africa traditional medicine. 2003;22(1):29-38. Available:www.chatsworthhs.org/.../Paper%20on%20African%20Medicine.pdf (Assessed: 22nd march 2012)
3. Oyebola DD. Yoruba traditional bonesetters: The practice of orthopaedics in a primitive setting in Nigeria. *J Trauma* 1980;20:312–322.
4. Engelmann H, Hallof J. Studies on the development of the medical occupational

- image in Egypt's early times. *Med Gesch.* 2004;23:9–42.
5. Hoff W. Traditional health practitioners as primary health care workers. *Trop Doct* 1997;27(1):52–55.
 6. Thanni LO, Akindipe JA, Alausa OK. Pattern and outcome of treatment of musculo-skeletal conditions by traditional bonesetters in south-west Nigeria. *Niger J Orthop Trauma.* 2003;2(2):112–115.
 7. Ikpeme IA, Udosen AM, Okereke – Okpa I. Patients' perception of traditional bone setting in Calabar. *Port Harcourt Med J.* 2007;1:104–108.
 8. Alonge TO, Dongo AE, Nottidge TE, Omololu AB, Ogunlade SO. Traditional bonesetters in south western Nigeria – friends or foes? *West Afr J Med.* 2004; 23(1):81–84.
 9. Ogunlusi JD, Okem IC, Oginni LM. Why patients patronize traditional bone setters. *Internet J Orthop Surg.* 2007;4(2).
 10. Onuminya JE, Onabowale BO, Obekpa PO, Ihezue CH. Traditional bone setter's gangrene. *Int Orthop.* 1999;23(2):111–112.
 11. Nwankwo OE, Katchy AU. Limb gangrene following treatment of limb injury by traditional bone setters (TBS): A report of 15 consecutive cases. *Niger Postgrad Med J.* 2005;12(4):57–60.
 12. Nwadiaro HC. Bonesetters' gangrene. *Niger J Med.* 2007;16(1):8–10.
 13. Brume J, Ijagha EO. Traditional bone setters and gas gangrene. *Lancet.* 1985; 1(8432):813.
 14. Bickler SW, Sanno-Duanda B. Bone setters gangrene. *J pediatr Surg.* 2000; 35(10):1431-1433.
 15. Nwandinigwe CU, Akwuba A. Limb amputations in children: Major risk factors in our environment. *Nig J. Othopaedics and trauma.* 2002;1(20):112-116.
 16. Garba ES, Deshi PJ, Iheirika KE. The role of traditional bonesetters in limb amputations in Zaria. *Nig. J. Surg Res.* 1999;1:21-24.
 17. Umaru RH, Gali BM, Ali N. Role of inappropriate traditional splintage in limb amputation in Maduigiri, Nigeria. *Annals of African Medicine.* 2004;3(3):138-140.
 18. Onuminya JE, Obekpa PO, Ihezue HC, Ukegbu ND, Onabowale BO, Major amputations in Nigeria; a plea to educate traditional bone setters. *Trop Doct.* 2000; 30(3):133-135.
 19. Foltin G, Fuchs S. Advances in pediatric emergency medical service systems. *Emerg Med Clin North Am.* 1991;9:459–74.
 20. Trautwein LC, Smith DG, Rivara FP. Pediatric amputation injuries: Etiology, cost, and outcome. *J Trauma.* 1996;41: 831–8.
 21. Boyle M, Tebbi CK, Mindell ER, Mettlin CJ. Adolescent adjustment to amputation. *Med Pediatr Oncol.* 1982;10:301–12.
 22. Desmond DM. Coping, affective distress, and psychosocial adjustment among people with traumatic upper limb amputations. *J Psychosom Res.* 2007;62: 15–21.
 23. Marsac ML, Donlon KA, Hildenbrand AK, Winston FK, Kassam-Adams N. Understanding recovery in children following traffic-related injuries: Exploring acute traumatic stress reactions, child coping, and coping assistance. *Clin Child Psychol Psychiatry.* 2014;19:233–43.
 24. Maksoud JG Jr, Moront ML, Eichelberger MR. Resuscitation of the injured child. *Semin Pediatr Surg.* 1995;4:93–9.
 25. White S.H posttraumatic stress disorder in the mother of a boy with traumatic limb amputation. *J Pediatr Psychol.* 1991;16: 103–15.
 26. Gupta A, Reeves B. Fijian seasonal scourge of mango tree falls. *ANZ J Surg.* 2009;79(12):898-900.
DOI: 10.1111/j.1445-2197.2009.05141.x
 27. Barss P, Dakulala P, Doolan M. Falls from trees and tree associated injuries in rural Melanesians. *Br Med J (Clin Res Ed).* 1984;289(6460):1717-20.
 28. Solagberu BA, Long bone fractures treated by traditional bone setters: A study of patients' behavior. *Trop Doct.* 2005;35(2): 106-108.
 29. Ibeanusi SE. Salvage of severely injured limbs in a developing country. *Port Harcourt Medical Journal.* 2012;6(1):301–305.
 30. Nolte J. *The Human Brain.* 3rd ed. St Louis, MO: Mosby; 1993.
 31. Rondinelli R. Ed. *AMA Guides to the Evaluation of Permanent Impairment.* 6th edn. American Medical Association; 2008.

32. Vocke AK, Schmid A. Osseous overgrowth after post-traumatic amputation of the lower extremity in childhood. *Arch Orthop Trauma Surg.* 2000;120:452–4.
33. Bickler SW, Sanno-Duanda B. Bone setters gangrene. *J Ped Surg* 2000; 35:1431-1433.
34. Odatuwa-Omagbemi DO, Enemudo RE, Enamine SE, Esezobor EE. Traditional bone setting in the Niger Delta region of Nigeria. *Niger J Med.* s2014;23(2):157-61.

© 2018 Diamond et al.; This is an Open Access article distributed under the terms of the Creative Commons Attribution License (<http://creativecommons.org/licenses/by/4.0>), which permits unrestricted use, distribution, and reproduction in any medium, provided the original work is properly cited.

Peer-review history:
The peer review history for this paper can be accessed here:
<http://www.sciencedomain.org/review-history/24628>