

## A Case of Takotsubo Cardiomyopathy - How We Uncovered the Diagnosis

V. Andova<sup>1</sup>, M. Otljanska<sup>1\*</sup>, H. Taravari<sup>1</sup>, A. Jovkovski<sup>1</sup>, N. Kostova<sup>1</sup>,  
E. Caparoska<sup>1</sup> and B. Zafirovska<sup>1</sup>

<sup>1</sup>University Clinic of Cardiology, Skopje, North Macedonia.

### **Authors' contributions**

*This work was carried out in collaboration among all authors. All authors read and approved the final manuscript.*

### **Article Information**

#### Editor(s):

(1) Dr. Thiago Andrade de Macêdo, Cardiology Division Heart Institute (InCor), Brazil.

#### Reviewers:

(1) Madiha Nooreen, Osmania University, India.

(2) Aasems Jacob, University of Kentucky, USA.

(3) Shiv Bagga, Tufts University School of Medicine, Massachusetts.

Complete Peer review History: <http://www.sdiarticle4.com/review-history/59073>

Case Study

**Received 24 May 2020**  
**Accepted 31 July 2020**  
**Published 15 August 2020**

### **ABSTRACT**

**Introduction:** Takotsubo cardiomyopathy (TTC) is a stress-induced condition characterized by transient apical hypokinesia and is usually caused by stress-induced catecholamine release with toxic action that leads to stunning myocardium. The aim of this report is to present the female patient with takotsubo cardiomyopathy with clinical presentation, diagnosis, treatment and follow up of this condition. This patient has good prognosis with complete left ventricular systolic function recovery typically occurring within weeks.

**Methods and Results:** The patient was a 62 years old woman without any history of heart disease. She was admitted with chest pain and electrocardiography (ECG) with ST segment elevation in the precordial leads and troponins suggesting acute anterior myocardial infarction (MI). The urgent coronary angiography which is performed didn't show obstructive coronary lesions. Echocardiography showed reduced left ventricle (LV) ejection fraction with LV apical ballooning and LV thrombus. Cardiac magnetic resonance imaging (MRI) showed localized hypokinesia of the mid septal segments and akinesis of all segments of the apex of the left ventricle and T2 hyperintensity consistent with myocardial transmural oedema in the same area with diffuse involvement. During the hospitalization patient was treated with single antiplatelet, anticoagulation therapy, diuretics, angiotensin-converting-enzyme inhibitors (ACE inhibitors) and beta blockers for treatment of heart

\*Corresponding author: E-mail: [magdalenaotljanska@gmail.com](mailto:magdalenaotljanska@gmail.com);

failure reduced Ejection fraction (HFrEF). At 2 months follow up ECG was normal with reversal of symptoms and regression of wall motion abnormalities at echocardiography. According to investigation results, a diagnosis of takotsubo syndrome (TTS) was established.

**Conclusion:** Takotsubo cardiomyopathy often presents as an acute coronary syndrome with ST segment changes, as ST-segment elevation and/or T-wave inversion. Clinical presentation is characterized by acute coronary artery disease, in the absence of obstruction, verified by coronarography. Diagnostic methods are very important to make true decision of takotsubo cardiomyopathy and coronary angiography and cardiac MRI are the best.

*Keywords: Acute coronary syndrome; left ventricle dysfunction; takotsubo cardiomyopathy.*

## 1. INTRODUCTION

Takotsubo cardiomyopathy, also known as stress cardiomyopathy and it is a sudden, transient cardiac syndrome that involves dramatic left ventricular apical akinesis and mimics acute coronary syndrome (ACS). It was first described in Japan in 1990 by Sato et al. [1]. Patients often present with chest pain, have ST-segment elevation on ECG, and have elevated cardiac enzyme levels consistent with MI. More than 90% of reported cases are women ages 58-70 and up to 5% of women suspected of having a heart attack having this disorder. However, when the patient undergoes cardiac angiography, LV apical ballooning is present, and there is no significant coronary artery stenosis [2-3].

Some authors have proposed a hypothesis that in some individuals, neurohormonal stimulation results in acute myocardial dysfunction, as reflected by the characteristic LV wall-motion abnormality of takotsubo cardiomyopathy. Whether this is triggered by multivessel spasm, thrombosis, epicardial vessel occlusion, or direct myocardial toxicity remains to be seen [4].

The exact etiology of takotsubo (stress) cardiomyopathy (broken heart syndrome) is still unknown, but several theories have been proposed and are under investigation and these include the following: multi vessel coronary artery spasm, impaired cardiac micro vascular function, impaired myocardial fatty acid metabolism, acute coronary syndrome (ACS) with reperfusion injury, endogenous catecholamine-induced myocardial stunning and micro infarction, underlying coronary endothelial dysfunction [5-8].

The modified Mayo Clinic criteria for diagnosis of takotsubo cardiomyopathy [9] can be applied to a patient at the time of presentation.

Presence of apical LV hypokinesis or akinesis, absence of obstructive coronary disease or angiographic evidence of acute plaque rupture, new ECG abnormalities (either ST-segment elevation and/or T-wave inversion) or modest elevation in the cardiac troponin level.

Patients with takotsubo (stress) cardiomyopathy should be treated as having ACS until proved otherwise.

The aim of this paper is to present the female patient with takotsubo cardiomyopathy with clinical presentation, diagnosis, treatment and follow up of this condition.

## 2. CASE PRESENTATION

A 62-year-old female patient was admitted to our institution complaining of chest pain and dyspnea. She described it as tightness in the chest and both of her forearms that irradiated to her back with difficulties in breathing. Chest pain started several hours before admission. Symptoms started after a stressful family event. From past medical history she only has hypertension controlled with ACE inhibitors - Enalapril 20 mg twice daily.

Laboratory analyses revealed high-sensitive troponin elevation. Urgent coronary angiography was performed after her initial evaluation and ruled out any significant coronary artery disease. Echocardiography showed reduced left ventricular ejection fraction with left ventricle apical ballooning, with thrombus in this segments of inter ventricular septum. Global longitudinal strain showed pathological values on apical region of LV (Fig. 2) Thrombus was present in the apex of the LV 25x17 mm.

## 3. DIAGNOSIS AND MANAGEMENT

Subsequently, according to ESC guidelines for differential diagnosis of myocardial infarction with no-obstructive coronary artery (MINOCA) the patient underwent cardiac magnetic resonance

imaging, which showed localized hypokinesia of the mid septal segments and akinesia of all segments of the apex of the LV and T2 hyperintensity consistent with myocardial transmural oedema in the same area with diffuse involvement. A thrombus was present in the apex

of the LV measuring 8x13 mm (Fig. 3). We had different thrombus sizes assessed by echocardiography and MRI because the diagnostic methods have different sensitivity and accuracy.

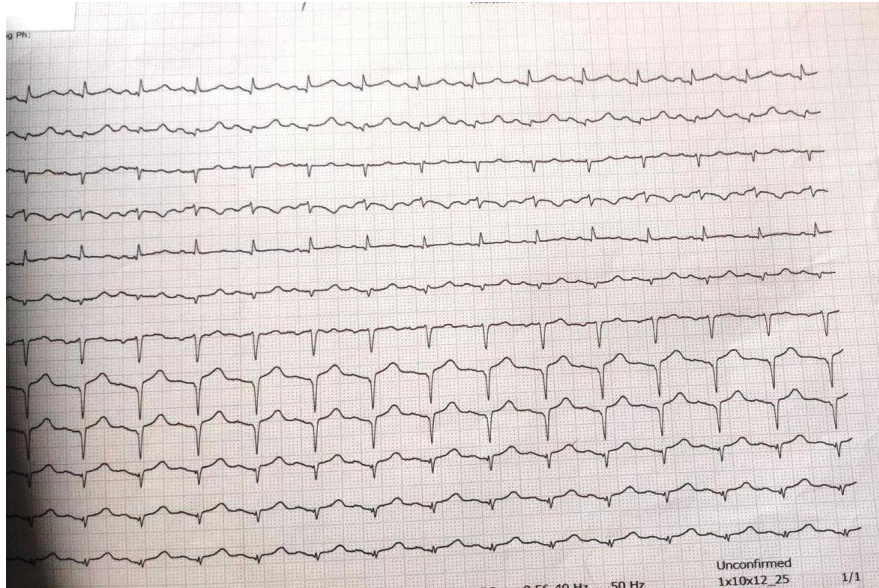


Fig. 1. Initial ECG showed ST segment elevation in the precordial leads V1 to V6, DI and aVL

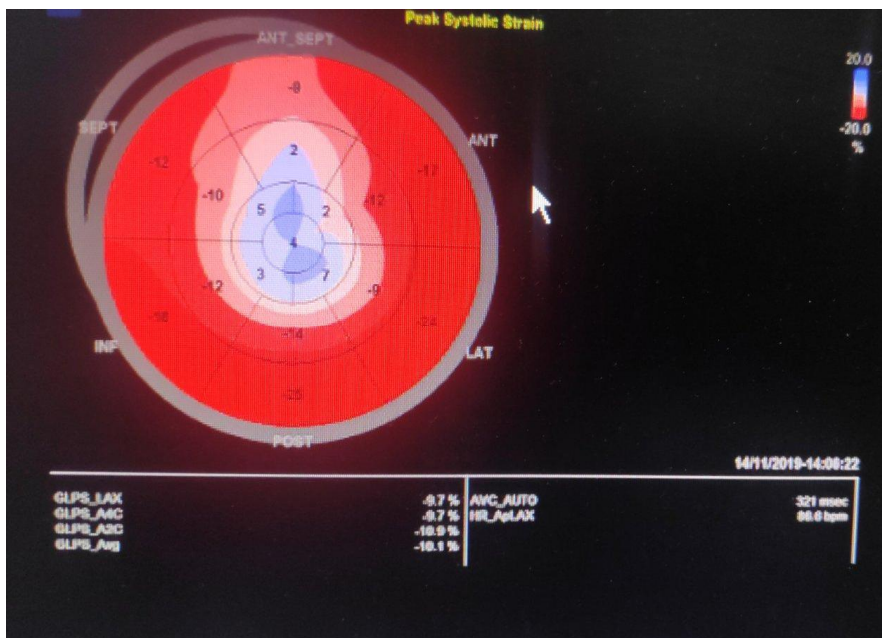
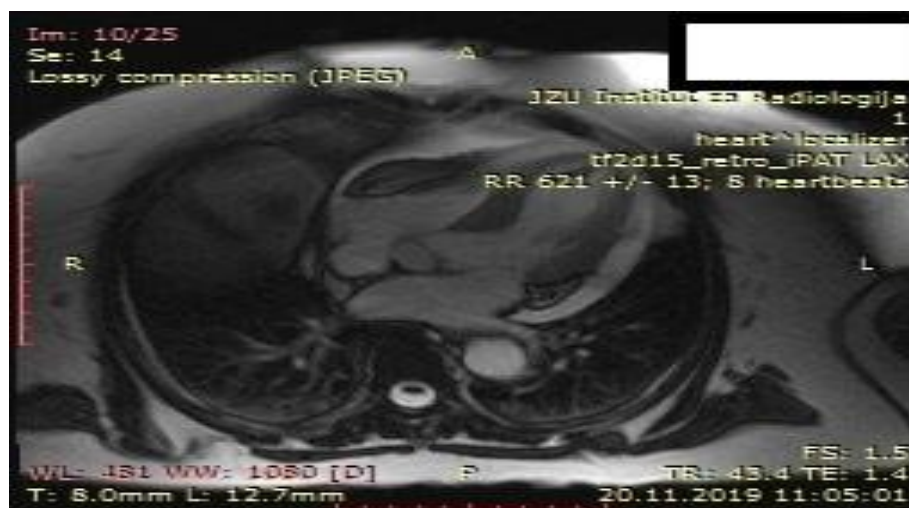
Fig. 2. Global longitudinal strain in takotsubo cardiomyopathy



**Fig. 3. Magnetic resonance of the heart in takotsubo cardiomyopathy**

Patient was treated with single antiplatelet, anticoagulation therapy for the apical thrombus, diuretics, beta blockers and ACE inhibitors for treatment of heart failure with reduce ejection fraction (HFrEF).

During hospitalization ECG changes evolved in localized inversion of T waves in anterolateral leads (Fig. 4).

**Follow up-outcome:** Patient was discharged in a stable condition with the same medications.

After 2 months follow up, control echocardiography showed regression of wall motion abnormalities and no thrombus present (Fig. 5).

According to all investigation and results, a diagnosis of takotsubo syndrome (TTS) was established.

#### 4. DISCUSSION

Takotsubo cardiomyopathy or apical ballooning syndrome (ABS) is a syndrome distinct from ACS. This disorder is named by "takotsubo" cardiomyopathy because during the acute phase of the syndrome, the left ventricle bulges and takes on a balloon shape. This syndrome is a relatively newly defined disease first described in Japan in 1990<sup>1</sup> and balloon shape is similar in appearance to the Japanese fisherman's takotsubo, meaning an octopus trap. In this report, we presented a case of female patient of takotsubo cardiomyopathy, detailing all

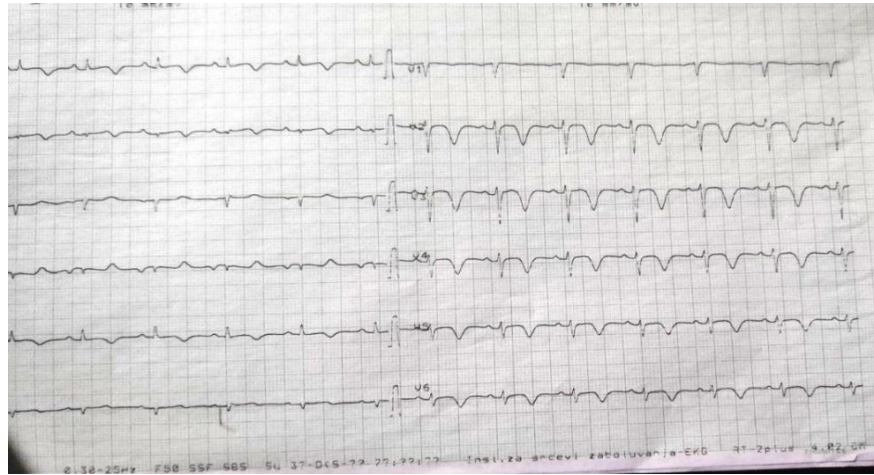
diagnostic modalities available for correct diagnosis in this condition.

Numerous studies have been published about cases with apical ballooning and transient left ventricular dysfunction after enduring severe emotional or physical stress [10-15].

From one of the largest series of patients with TTS published in the New England Journal of Medicine it's clear that this syndrome is much more common than previously imagined [15]. According to this study in all of the cases with TTS there is a trigger that is usually an event of physical or emotional stress that led to the acute presentation.

In the majority of cases in TTS there is a non-obstructive CAD with signs of myocardial ischemia as chest pain, ECG changes, elevated cardiac biomarkers, as well as ventricular dysfunction and is usually caused by severe and prolonged microvascular constriction.

In our case TTC induced a reversible LV apical akinesia/dyskinesia resulting in myocardial stunning that was diagnosed on advance echocardiography and MRI. Clinical presentation was characterized by evidence of acute coronary artery disease, but in the absence of obstruction, verified by coronarography. Also the data from the patients' history as age and gender, the postmenopausal context, and the transient large apical and mid ventricular segments wall motion dysfunctions, favored the diagnosis of TTC [13].



**Fig. 4. ECG changes evolved in localized inversion of T waves in anterolateral leads**



**Fig. 5. Global longitudinal strain after 2 months**

Reversal of the symptoms and regression of wall motion abnormalities on advance echocardiography at follow up was the key finding in our investigations.

Prognosis of patients with takotsubo cardiomyopathy generally is favourable but sometimes it is associated with increased percentage of arrhythmias, intraventricular thrombi, and cardiogenic shock with death. The most common clinical complication is heart failure. Correct diagnosis and evidence based treatment is essential in successful management of these syndrome.

## 5. CONCLUSION

Takotsubo cardiomyopathy often presents as an acute coronary syndrome with ST segment changes, as ST-segment elevation and/or T-wave inversion. Clinical presentation is characterized by acute coronary artery disease, in the absence of obstruction, verified by coronarography. Reversal of symptoms and regression of wall motion abnormalities at echocardiography at follow up is the key finding of this condition. Medications used to treat takotsubo cardiomyopathy in this case include antiplatelet, anticoagulation therapy for the

apical thrombus, diuretics, beta blockers and ACE inhibitors for treatment of heart failure with reduce ejection fraction (HFrEF). Additionally, we must acknowledge that takotsubo cardiomyopathy represents etiologic differential diagnosis of MINOCA. Diagnostic methods are very important to make true decision of takotsubo cardiomyopathy and MINOCA.

## CONSENT

We have informed consent obtained from patient.

## ETHICAL APPROVAL

As per international standard or university standard written ethical approval has been collected and preserved by the author(s).

## COMPETING INTERESTS

Authors have declared that no competing interests exist.

## REFERENCES

1. Sato H, Tateishi H, Uchida T, et al. Kodama K, Haze K, Hon M, eds. Clinical aspect of myocardial injury: From ischaemia to heart failure. Tokyo: Kagakuhyouronsya. 1990;56-64.
2. Dawson DK. Acute stress-induced (takotsubo) cardiomyopathy. *Heart*. 2018; 104(2):96-102.
3. Kurisu S, Kihara Y. Clinical management of takotsubo cardiomyopathy. *Circ J*. 2014;78(7):1559-66.
4. Lindsay J, Paixao A, Chao T, Pichard AD. Pathogenesis of the takotsubo syndrome: A unifying hypothesis. *Am J Cardiol*. 2010;106(9):1360-3.
5. Afonso L, Bachour K, Awad K, Sandidge G. Takotsubo cardiomyopathy: Pathogenetic insights and myocardial perfusion kinetics using myocardial contrast echocardiography. *Eur J Echocardiogr*. 2008;9(6):849-54.
6. Angelini P, Uribe C. Is transient takotsubo syndrome associated with cancer? Why, and with what implications for oncocardiology? [editorial]. *J Am Heart Assoc*. 2019;8(15):e013201.
7. Lindsay J, Paixao A, Chao T, Pichard AD. Pathogenesis of the takotsubo syndrome: A unifying hypothesis. *Am J Cardiol*. 2010;106(9):1360-3.
8. Khallafi H, Chacko V, Varveralis N, Elmi F. Broken heart syndrome: Catecholamine surge or aborted myocardial infarction? *J Invasive Cardiol*. 2008;20(1):E9-13.
9. Kawai S, Kitabatake A, Tomoike H. Guidelines for diagnosis of takotsubo (apulla) cardiomyopathy. *Circ J*. 2007; 71(6):990-2.
10. Pavin D, Le Breton H, Daubert C. Human stress cardiomyopathy mimicking acute myocardial syndrome. *Heart*. 1997;78(5): 509-511.
11. Kawai S, Suzuki H, Yamaguchi H, et al. Ampulla cardiomyopathy ('takotsubo' cardiomyopathy) - reversible left ventricular dysfunction: With ST segment elevation. *Japanese Circulation Journal*. 2000;64(2): 156-9.
12. Brandspiegel HZ, Marinchak RA, Rials SJ, Kowey P. A broken heart. *Circulation*. 1998;98(13):1349.
13. Tsuchihashi K, Ueshima K, Uchida T, et al. Transient left ventricular apical ballooning without coronary artery stenosis: A novel heart syndrome mimicking acute myocardial infarction. *Journal of the American College of Cardiology*. 2001; 38(1):11-18.
14. Ghadri JR, Ruschitzka F, Lüscher TF, Templin C. Takotsubo cardiomyopathy: Still much more to learn. *Heart*. 2014; 100:1804-1812.
15. Templin C, Ghadri JR, Diekmann J, et al. Clinical features and outcomes of takotsubo (stress) cardiomyopathy. *N Engl J Med*. 2015;373:929-938.

© 2020 Andova et al.; This is an Open Access article distributed under the terms of the Creative Commons Attribution License (<http://creativecommons.org/licenses/by/4.0>), which permits unrestricted use, distribution, and reproduction in any medium, provided the original work is properly cited.

### Peer-review history:

The peer review history for this paper can be accessed here:  
<http://www.sdiarticle4.com/review-history/59073>