

Patent Ductus Arteriosus Closure by Paracetamol in a Critical Preterm Infant after Late Recanalization

Abdelmonem Helal¹, Naif Alkhushi¹ and M. O. Galal^{1*}

¹King Faisal Specialist Hospital and RC, Jeddah, KSA, Saudi Arabia.

Authors' contributions

This work was carried out in collaboration among all authors. Author MOG suggested the topic, wrote the protocol and wrote the first draft of the manuscript. Author AH collected the data and authors AH and NA managed the analyses of the study. Authors AH and MOG managed the literature searches. All authors read and approved the final manuscript.

Article Information

Editor(s):

(1) Dr. Christopher Edet Ekpenyong, University of Uyo, Nigeria.

Reviewers:

(1) M. Aynul Rifaya, Anna University, India.

(2) Bharathi Balachander, St. John's Medical College, India.

Complete Peer review History: <http://www.sdiarticle4.com/review-history/60064>

Case Report

Received 16 June 2020
Accepted 22 August 2020
Published 01 September 2020

ABSTRACT

Cyclooxygenase (COX) inhibitors form the first line of treatment for patent ductus arteriosus (PDA) in preterm neonates. However, their efficacy decreases with increasing postnatal age. Paracetamol can be used when COX inhibitors are contraindicated and in advanced postnatal age. We describe a late preterm neonate (five weeks postnatal age, 1550 g birth weight) with a hemodynamically significant PDA, where COX inhibitor therapy could not be initiated due to spontaneously perforated necrotizing enterocolitis that was treated surgically. At five weeks postnatal age and body weight of 1800 g intravenous paracetamol was started. Over a 3-day course, it led to complete closure of the PDA. With follow up three months after treatment, recanalization occurred but did not need further attention.

Keywords: Paracetamol; Patent Ductus Arteriosus (PDA); necrotizing enterocolitis; preterm infant.

*Corresponding author: E-mail: ogalal@yahoo.com, mogalal1@yahoo.de;

1. INTRODUCTION

Persistently patent ductus arteriosus (PDA) in preterm infants remains difficult to treat. The closure rates for patent ductus arteriosus in premature infants using Cyclooxygenase (COX) inhibitors are 70-85%. These medications need to be used cautiously due to various contraindications and potential side effects [1]. Additionally, their effectiveness decreases with postnatal age [2]. If COX inhibitors fail to close the PDA or are contraindicated the PDA can be surgically ligated if needed. Surgical ligation is associated with significant short term morbidities and impaired neurological outcome in the long term [3]. Recently, there is increasing evidence supporting the use of Paracetamol as an alternative drug for PDA closure in preterm neonates [4]. Its effectiveness with increasing postnatal age is still under evaluation [5,6]. It is worthwhile mentioning that potential complications of paracetamol treatment were suggested to be hepatic failure and late onset autism [7,8].

Here, we describe a patient where at five weeks postnatal age (37 weeks postconceptual age), a hemodynamically significant PDA closed using paracetamol intravenous therapy. However, it showed late tiny recanalization of PDA.

2. CASE REPORT

A 32 year old 32 weeks pregnant lady underwent emergency cesarean section due to premature contractions. The birth weight of the premature male neonate was 1550 g. The baby was diagnosed antenatally to have a non-immune hydrops fetalis caused by atrial arrhythmias which was treated intrauterine with flecainide and digoxin. He needed resuscitation and intubation after delivery, because of hydrops fetalis. An echocardiographic study on the first day of life showed a three mm large PDA which was treated conservatively by constraining fluid. On the fourth day of life, PDA was closed but the patient developed prolonged attacks of atrial arrhythmias (Fig. 1). Twelve leads electrocardiogram showing transient sinus rhythm after adenosine injection then back to atrioventricular re-entry tachycardia. Over 48 hours the rhythm was converted successfully to sinus rhythm with amiodarone infusion after the failure of direct current cardioversion.

On the 14th day of life, the patient developed perforated necrotizing enterocolitis (NEC) after

the first oral feeding trial, which was treated surgically with an ileostomy. The patient was treated from sepsis and taking post-operative care for 10 days. (Fig. 2) On day 33 of life, an echocardiogram showed the PDA to be 3 mm in diameter. There was wide pulse pressure, PDA to weight ratio was two and the patient remained ventilated. Thereafter, Paracetamol intravenous (10 mg/kg/dose, every 6 h) was started and the PDA size was followed up by echocardiography on day two of the treatment course [6]. This showed significant restriction of PDA size and complete closure on day 3 of the treatment course (Fig. 3). Three days after discontinuing Paracetamol, an echocardiogram showed no recanalization of PDA. (Fig. 3d) There were no major adverse effects, such as oliguria, thrombocytopenia, or intestinal dysfunction. Patient was successfully weaned off from mechanical ventilation and remained hemodynamically stable and discharged home with a bodyweight of 1.9 kg, 10 days after extubation. Three months after discharge, patient showed recanalization of PDA. The infant was otherwise clinically stable and did not need further medication.

3. DISCUSSION

A preterm neonate of five weeks postnatal age is presented with a hemodynamically significant PDA closed after paracetamol intravenous therapy.

Few studies were published on the late onset closure of PDA by paracetamol. These studies were done on a small number of patients and showed controversial outcomes [9]. We thought to present this case to document efficacy of this treatment, even in five weeks old premature infants. Additionally, our case showed that this treatment modality can also be safely used in very critical neonates, who are hemodynamically compromised due to recurrent arrhythmias and also were treated from necrotizing enterocolitis. Interestingly, we did not meet any complications from paracetamol therapy.

Our case showed that the late use of intravenous Paracetamol in the treatment of PDA in infants who are candidates for PDA surgical ligation is worth further exploration. Due to the history of gastrointestinal surgery and the presence of sepsis, other medical lines of treatment like indomethacin or ibuprofen were contraindicated. A potential benefit of such treatment could be that the gradual closure of the PDA diameter

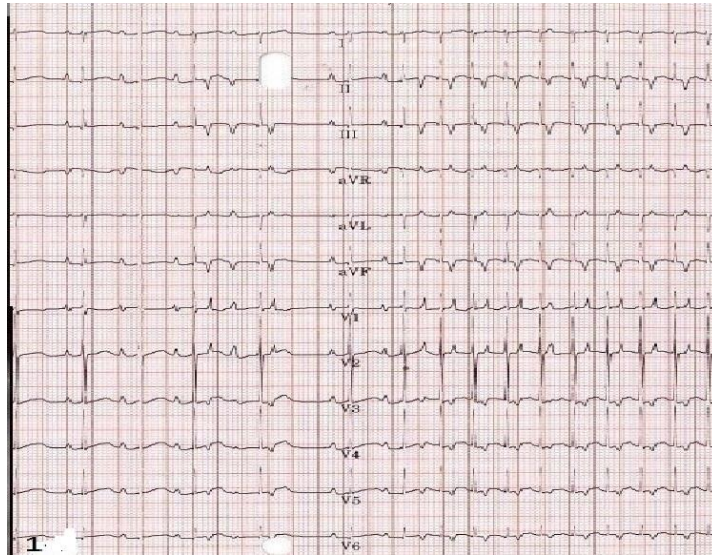


Fig. 1. Twelve leads electrocardiogram showing atrioventricular re-entry tachycardia after transient sinus rhythm after adenosine injection

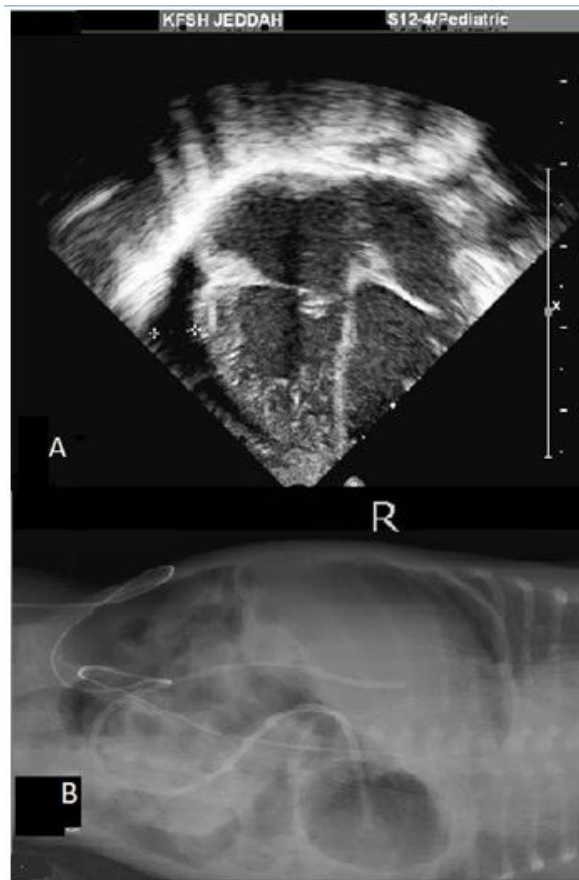


Fig. 2. A: Echocardiographic apical four chamber view showing pericardial effusion as a sign of hydrops fetalis; B: Lateral abdominal x-ray showing pneumoperitoneum as a sign of perforated necrotizing enterocolitis

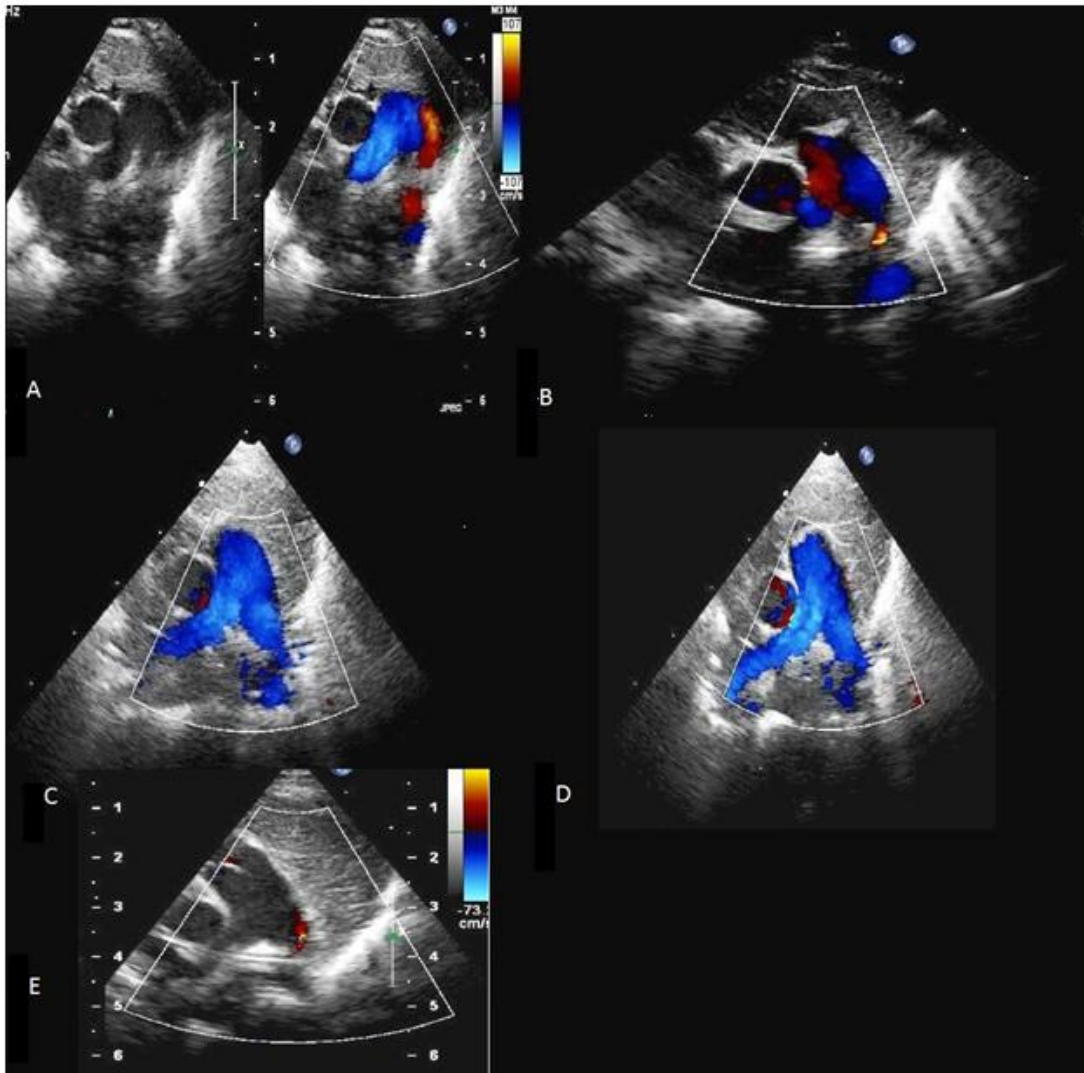


Fig. 3. A: Echocardiographic ductal view showing large PDA; B: Echocardiographic short axis view showing restriction of PDA size after two days of paracetamol treatment; C: Echocardiographic short axis view showing total closure of PDA on day three of treatment; D: Echocardiographic short axis view showing no recanalization of PDA after three days of treatment; 3E: Echocardiographic short axis view showing recanalization of PDA after 3 months follow up

occurring with the use of such therapy may lead to a lesser physiological impact than the sudden closure through surgical ligation. The infant in this report was exposed to the effect of the ductal shunt for a prolonged period. Therefore, ventilator dependency may be a consequence of long-term pulmonary over circulation. Similarly, chronic systemic hypoperfusion due to left to right shunting may explain the incidence of NEC. Interestingly, in our case and three months after discharge, echocardiography revealed recanalization of

PDA, though the patient did not need a change of management. Recanalization at early follow up was also mentioned by others [10] and in their case treated by administering another course of paracetamol.

Both cases show the importance of regular follow up after such treatment. It is speculated whether after discontinuation of intravenous paracetamol this should be followed by a few days of oral paracetamol to possibly avoid such recanalization.

4. CONCLUSION

In conclusion, we believe that paracetamol might be used as rescue management for the closure of preterm PDA whenever lines of treatment either failed or are contraindicated. Our case also emphasizes the importance of regular follow up.

CONSENT

As per international standard or university standard, patient's written consent has been collected and preserved by the authors.

ETHICAL APPROVAL

It is not applicable.

COMPETING INTERESTS

Authors have declared that no competing interests exist.

REFERENCES

1. Ohlsson A, Walia R, Shah SS. Ibuprofen for the treatment of patent ductus arteriosus in preterm or low birth weight (or both) infants. *Cochrane Database Syst Rev*. 2015;2:CD003481.
2. Achanti B, Yeh TF, Pildes RS. Indomethacin therapy in infants with advanced postnatal age and patent ductus arteriosus. *Clin Invest Med*. 1986;9:250-3.
3. Hermes-DeSantis ER, Clyman RI. Patent ductus arteriosus: Pathophysiology and management. *J Perinatol*. 2006; 26(Suppl 1):S22-3.
4. Ohlsson A, Shah PS. Paracetamol (acetaminophen) for patent ductus arteriosus in preterm or low-birth-weight infants. *Cochrane Database Syst Rev*. 2015;3:CD010061.
5. Roofthoof DW, van Beynum IM, de Klerk JC, van Dijk M, van den Anker JN, Reiss IK, et al. Limited effects of intravenous paracetamol on patent ductus arteriosus in very low birth weight infants with contraindications for ibuprofen or after ibuprofen failure. *Eur J Pediatr*. 2015;174: 1433-40.
6. EL-Khuffash A, James AT, Cleary A, Semberova J, Franklin O, Miletin J. Late medical therapy of patent ductus arteriosus using intravenous paracetamol. *Arch Dis Child Fetal Neonatal Ed*. 2015;100(3): F253-6. DOI: 10.1136/archdischild-2014-307930 Epub 2015 Feb 4. PubMed PMID: 25653299
7. Tan Z. H., Baral V. R. Principles of clinical management of patent ductus arteriosus in extremely preterm neonates. *Current Pediatric Reviews*. 2016;12(2):83–97. DOI:10.2174/157339631202160506001309
8. Bauer AZ, Kriebel D. Prenatal and perinatal analgesic exposure and autism: An ecological link. *Environ Health*. 2013; 12:41. DOI: 10.1186/1476-069X-12-41
9. EL-Khuffash A, James AT, Cleary A. Late medical therapy of patent ductus arteriosus using intravenous paracetamol. *Archives of Disease in Childhood - Fetal and Neonatal Edition*. 2015;100:F253-F256.
10. Dang D, Wang D, Zhang C, Zhou W, Zhou Q, Wu H. Comparison of oral paracetamol versus ibuprofen in premature infants with patent ductus arteriosus: A randomized controlled trial. *PLoS One*. 2013;8(11): e77888. DOI: 10.1371/journal.pone.0077888 eCollection 2013. PubMed PMID: 24223740; PubMed Central PMCID: PMC3817181.

© 2020 Helal et al.; This is an Open Access article distributed under the terms of the Creative Commons Attribution License (<http://creativecommons.org/licenses/by/4.0>), which permits unrestricted use, distribution, and reproduction in any medium, provided the original work is properly cited.

Peer-review history:

The peer review history for this paper can be accessed here:
<http://www.sdiarticle4.com/review-history/60064>