



Anaesthetic Management of Left Cerebellopontine Angle Acoustic Nerve Schwannoma in Sitting Position with Intraoperative Electromyographic Facial Nerve Monitoring

**Wankhade Prachi^{a#}, Roshan Nisal^{a#}, Swathi Reddy^{a*#}, Neeta Verma^{a#},
Jui Jadhav^{a#} and Nikhil Bhalerao^{a#}**

^a Department of Anaesthesia, Jawaharlal Nehru Medical College, Sawangi Meghe, Wardha, Maharashtra, India.

Authors' contributions

This work was carried out in collaboration among all authors. All authors read and approved the final manuscript.

Article Information

DOI: 10.9734/JPRI/2021/v33i60B34880

Open Peer Review History:

This journal follows the Advanced Open Peer Review policy. Identity of the Reviewers, Editor(s) and additional Reviewers, peer review comments, different versions of the manuscript, comments of the editors, etc are available here: <https://www.sdiarticle5.com/review-history/80592>

Case Study

Received 15 October 2021
Accepted 20 December 2021
Published 25 December 2021

ABSTRACT

A case of left cerebellopontine angle acoustic nerve schwannoma in sitting position with electromyographic(EMG) monitoring for facial nerve was managed. The 40 year old male, ASA II, presented with complaints of difficulty in walking, left sided hearing loss, diminution of vision since 3 years and Magnetic Resonance Image (MRI)suggestive of left CPA acoustic nerve schwannoma. Patient was operated under general anaesthesia in sitting position with Mayfield clamp on head without using muscle relaxant as the plan was to use EMG monitoring during tumor resection. Anesthesia was maintained with sevoflurane and propofol and no muscle relaxant was used, yet patient was immobile. Throughout the procedure haemodynamic stability was maintained with noradrenaline injection. Procedure was uneventful with complete excision of tumor and without damaging the facial nerve. Excision of this deep-seated tumor in sitting position without using muscle relaxant is very difficult to manage. This surgery was very challenging from anaesthetic point of view as sitting position itself increases the risk of complications and avoiding movement of patient with Mayfield clamp without using muscle relaxant was a tough job.

[#] Assistant Professor;

⁼ Junior Resident;

[°] Dr.;

*Corresponding author: E-mail: swathireddy17@gmail.com;

Keywords: CPA; sitting position; EMG monitoring; no muscle relaxant.

1. INTRODUCTION

The sitting position was introduced in clinical practice by De Marte in 1973 [1]. However, it has been declining in popularity since the 1980s due to high incidence of complications. Sitting position has been used for resection of tumors in cerebellopontine angle, pineal region, other technically difficult tumors in infratentorial region as well as surgeries of cervical spine. The advantages of this position is that it provides drainage of CSF and blood, provides easy access to airway and promotes favorable changes in ventilatory mechanics. This position has several life threatening complications such as venous air embolism, postural cardiovascular effects because of general anesthesia, macroglossia, pneumocephalus, quadriplegia and peripheral nerve injury [2].

Intraoperative electromyographic (EMG) monitoring of the facial nerve during acoustic neuroma resection allows the early detection of surgical stimulation and reduces nerve dysfunction postoperatively [3]. Acoustic nerve schwannoma are the most common tumors of the cerebellopontine angle (CPA) [4], accounting for

more than 90% of all such tumors with the risk of injuring facial nerve during surgeries. Usage of intraoperative EMG monitoring will definitely reduce the risk of damaging facial nerve, but becomes more challenging for an anaesthetist to maintain motionless patient in sitting position with Mayfield clamp on head of the patient. A case of left CP angle tumor posted for excision in sitting position with EMG monitoring was managed in our institute.

2. CASE REPORT

A 40 year old (45 kg, 155 cm) male brought to the hospital with complaints of difficulty in walking, left sided hearing loss and diminution of vision for the past 3 years. MRI was done which revealed a well marginated heterogeneously enhancing extra axial mass lesion in left CP angle cistern suggestive of acoustic nerve schwannoma. He was referred for excision of the tumour. Thorough preoperative checkup was done; HRCT was S/O a solitary pulmonary nodule in left upper lobe. According to radiologist it was infective etiology. All routine workups were done including 2D ECHO which was normal.

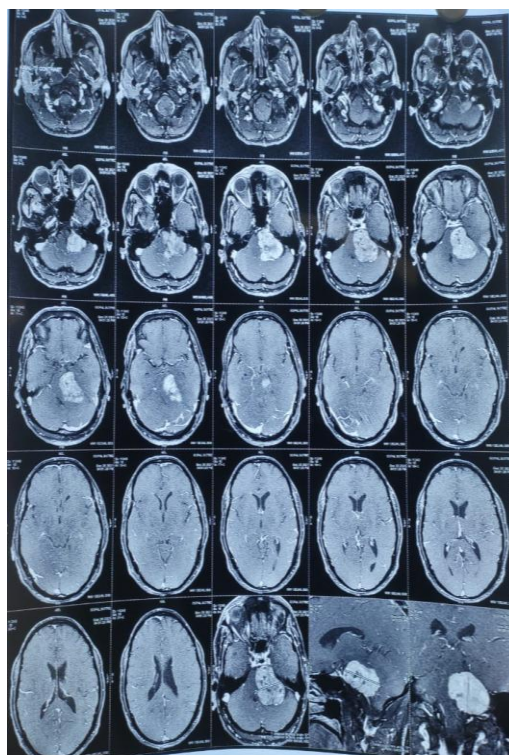


Fig. 1. Preoperative MRI scan

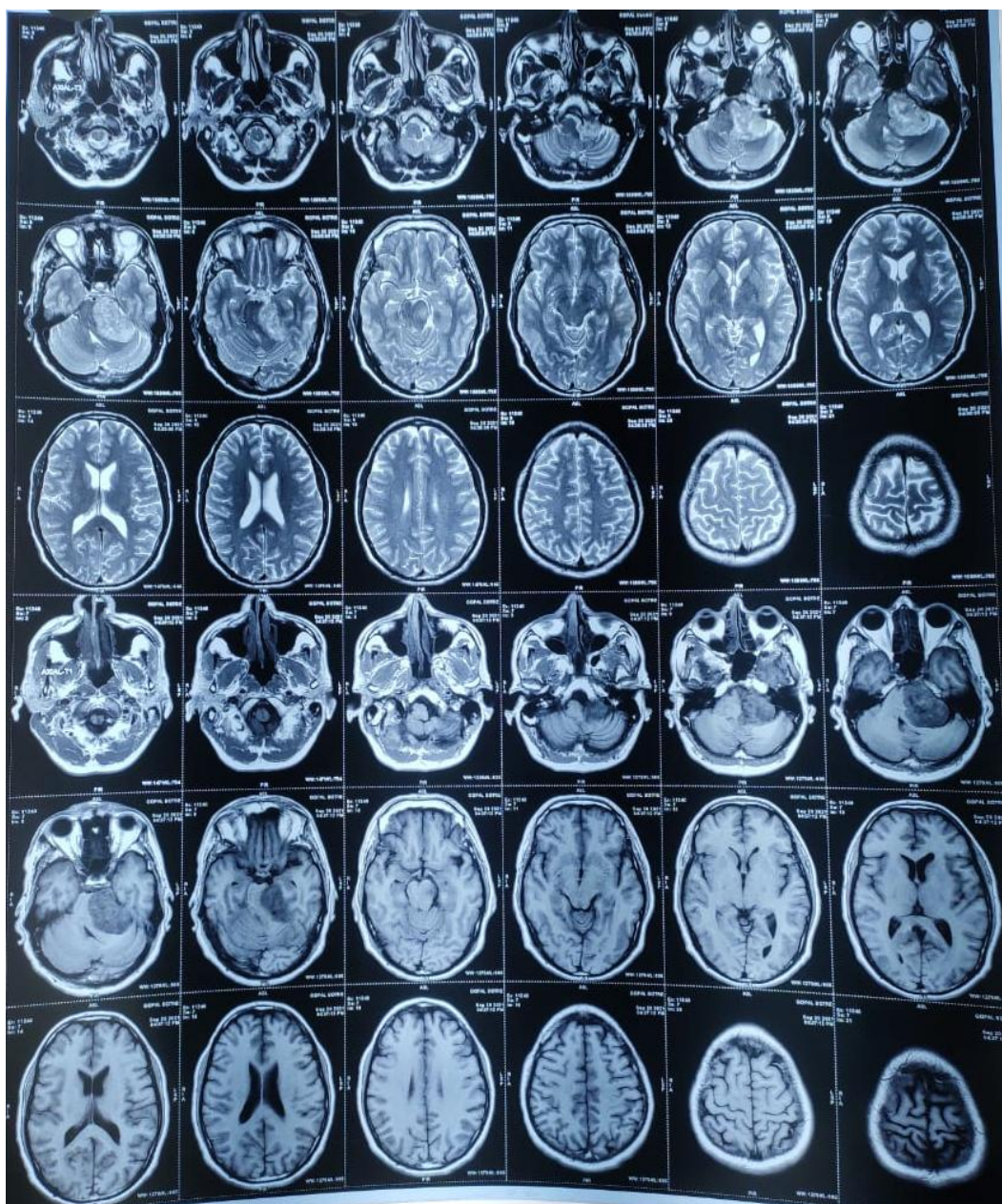


Fig. 2. T2 image of MRI

Patient was transferred to OT All ASA monitors were attached, 18G Intracath was secured intravenous fluid NS started. Patient was preoxygenated with 100% oxygen at 5 lit/min of oxygen and premedicated with inj. lidocaine 2% 1.5 mg/kg. Induction done with Inj. thiopentone 5 mg/kg and Inj. fentanyl 2mcg/kg after that ventilation was confirmed with bag and mask and muscle relaxant Inj. vecuronium 0.1mg/kg was given. Patient was ventilated for 3 minutes and intubated with ET tube size 8 mm. After confirming the air entry is equal on both sides, ET tube was fixed. Left radial artery was

cannulated for direct arterial pressure monitoring and arterial blood gas analysis intraoperatively. Triple lumen central line was cannulated in right subclavian vein. Anaesthesia was maintained with sevoflurane (MAC 0.8 -0.9) and oxygen and air (40%-60%). The bladder was catheterised for urine output monitoring. After the continuous observation of central venous pressure (CVP), arterial pressure and peak pressures, patient was slowly kept in sitting position without disturbing the hemodynamic parameters. Knees were kept at the level of the heart while shoulders were strapped to the operating table

from behind to avoid drooping. Over flexion of neck was avoided; pillows were placed below thighs and legs on both sides and pressure points were padded properly; a Mayfield frame was used, which was clamped to the side rails of the operating table to make the head and trunk

immobile with respect to each other. Before fixing the frame to the scalp inj. fentanyl 1 mcg/ kg was administered. After final positioning, Arterial line transducer was zeroed at the level of the middle ear. Intraoperative analgesic was maintained with fentanyl 1 mcg/kg/hr.

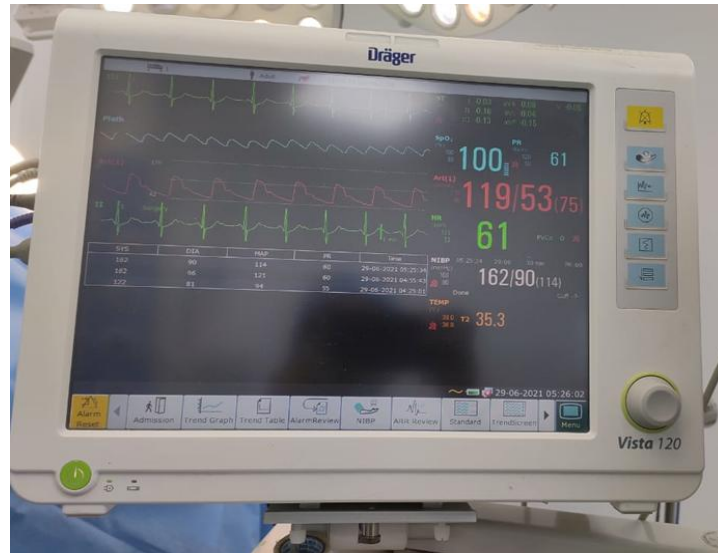

Fig. 3. Intra operative vitals

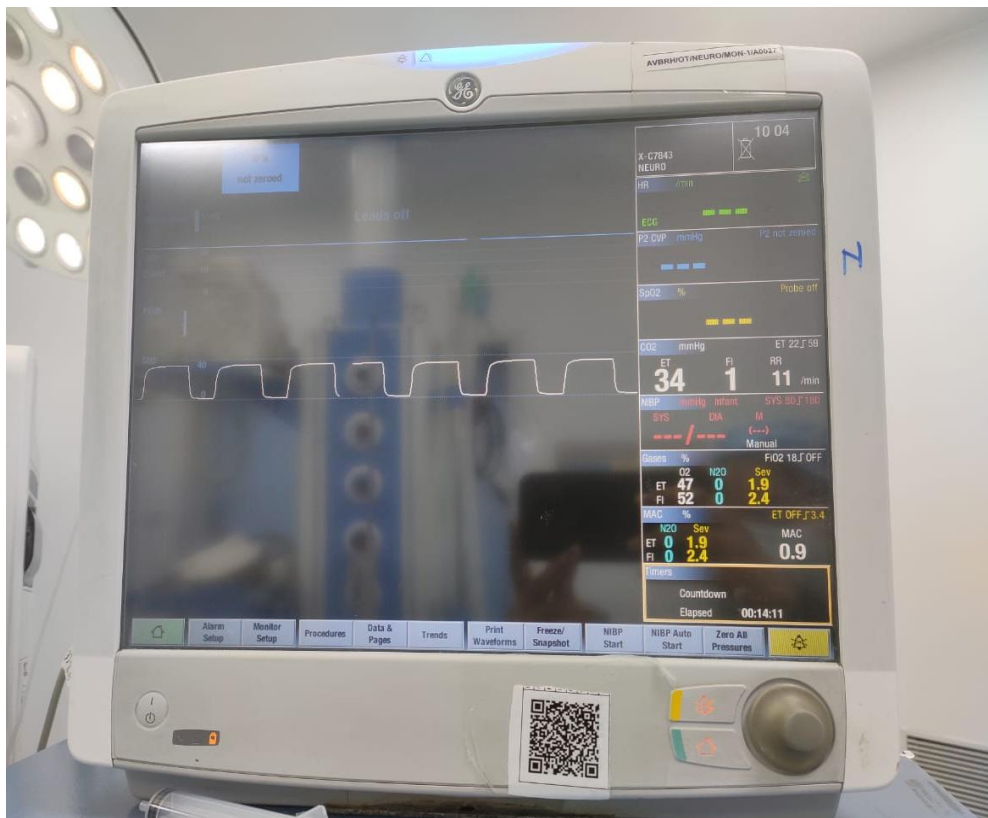

Fig. 4. Intraoperative EtCO2 monitoring

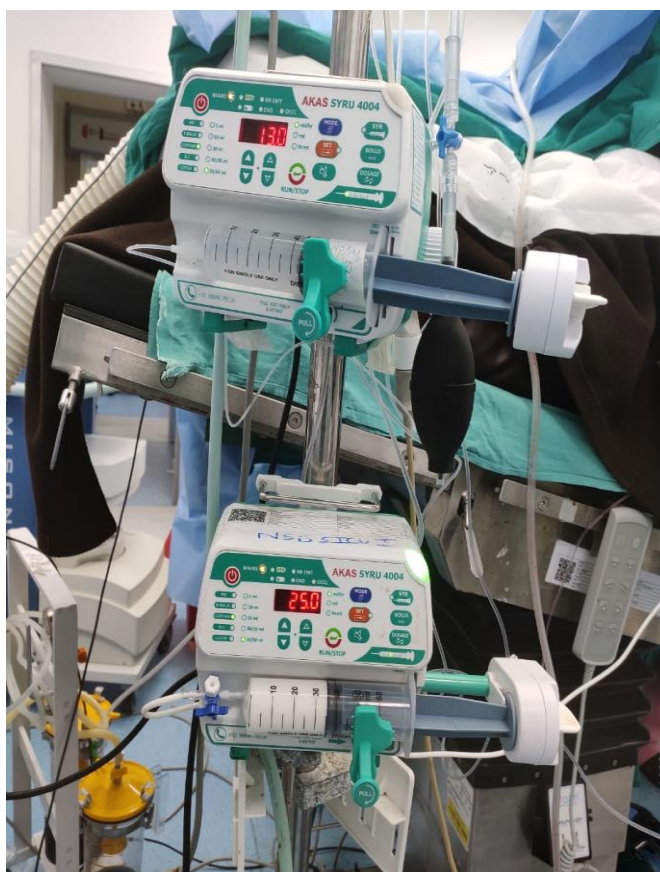

Fig. 5. intraoperative noradrenaline and propofol infusions

As the surgeon planned for facial nerve monitoring, the patient was maintained on inj. propofol infusion at 0.2 mg/kg/hr and Sevoflurane MAC was kept at 0.5 to 0.6 %; inj noradrenaline infusion was started at 4 ml/hr to maintain MAP between 70mmHg to 90 mmHg. All vital parameters were maintained at a stable rate throughout the procedure. Serial arterial blood gases monitoring was done. There was no episode of air embolism throughout the surgery which is the most devastating complication in sitting position.

The surgery was completed in 11 hours without complications; patient was moved to the intensive care unit (ICU) with ET tube insitu. He was put on inj. midazolam 5mg/hr with inj. fentanyl 1mcg/kg boluses every 2 hours for the night and extubated the next day after stopping sedation. Patient was fully conscious and oriented, obeying commands, GCS was E4V5M6 and no facial palsy was present.

3. DISCUSSION

CPA tumors are mostly benign, slow-growing tumors with low potential for malignancy (~1%)

(1). Between 5 and 10% of all intracranial tumors are located in the cerebellopontine angle [5]. The most common tumors at the CPA are vestibular schwannoma, meningioma, and epidermoid tumors [6]. Vestibular schwannoma accounts for 75 to 85% of all CPA tumors; Schwannomas are the primary lesion of cranial nerves involving trigeminal, facial, glossopharyngeal, vagus and sometimes even accessory cranial nerve [7]. The diagnosis of CPA tumors is based on history, physical examination, audiometric and radiological evaluation. Magnetic Resonance Image (MRI) is the gold standard for the diagnosis of CPA tumors. Treatment options for CPA tumors include observation, radiation therapy or microsurgery [8]. In patients undergoing acoustic neuroma resection, intraoperative EMG monitoring of the facial nerve has resulted in improved preservation of facial nerve function postoperatively [1]. The anaesthetic management of these patients should not only provide an immobile patient but also provide an optimal environment for facial EMG monitoring. The advantages of sitting position includes improved surgical access to the posterior fossa by facilitating gravity assisted

drainage of blood and CSF [9] and decreasing intracranial pressure (ICP) .It also improves surgical orientation, access to the midline structures and decreases the amount of surgical retraction needed to gain access to deeper structures. This position however has many disadvantages such as venous air embolism accounting for 25%-75% cardiovascular instability, macroglossia, quadriplegia and pneumocephalus [10]. Patients in the sitting position must be returned to the supine position rapidly for resuscitative measures in case of an acute cardiovascular collapse. From the surgical aspect, the sitting position gives good surgical access to the operative site [11], improves venous drainage, gives a better view of facial area for monitoring evoked responses from cranial nerve stimulation and allows for better ventilation. Conversely, the sitting position can present complications such as air emboli, postural hypotension and serious cardiac arrhythmias due to surgical stimulation of cranial nerves and brainstem. Precordial Doppler or transesophageal echocardiography monitoring improves the detection of small venous air embolism enabling its early treatment and diminishing its consequences [12]. Use of Train of Four (TOF) and Bispectral index(BIS) monitoring [13] could have been more helpful in this patient, as these are the conventional methods to assess the requirement of muscle relaxant and depth of anaesthesia.

4. CONCLUSION

Ideal positioning means, the position which provides good surgical access without any harm to the patient. Sitting position has many advantages, but very high chances of catastrophic complication. EMG monitoring is the advanced technology used during surgery for identification and dissection of lower cranial nerves during surgery. Accepting the challenge of sitting position without using of muscle relaxant ,we successfully managed this patient without any complications.

DISCLAIMER

The products used for this research are commonly and predominantly use products in our area of research and country. There is absolutely no conflict of interest between the authors and producers of the products because we do not intend to use these products as an avenue for any litigation but for the advancement of knowledge. Also, the research was not funded by

the producing company rather it was funded by personal efforts of the authors.

CONSENT

As per international standard or university standard, patients' written consent has been collected and preserved by the author(s).

ETHICAL APPROVAL

As per international standard or university standard written ethical approval has been collected and preserved by the author(s).

COMPETING INTERESTS

Authors have declared that no competing interests exist.

REFERENCES

1. Porter JM, Pidgeon C, Cunningham AJ. The sitting position in neurosurgery: a critical appraisal. *British journal of anaesthesia*. 1999;82(1):117-28.
2. Albin. MD MS, Babinski M, Maroon JC, Jannetta PJ. Anesthetic management of posterior fossa surgery in the sitting position. *Acta Anaesthesiologica Scandinavica*. 1976;20(2):117-28.
3. Amano M, Kohno M, Nagata O, Taniguchi M, Sora S, Sato H. Intraoperative continuous monitoring of evoked facial nerve electromyograms in acoustic neuroma surgery. *Acta neurochirurgica*. 2011;153(5):1059-67.
4. Kankane VK, Warade AC, Misra BK. Nonvestibular schwannoma tumors in the cerebellopontine angle: A single-surgeon experience. *Asian journal of neurosurgery*. 2019;14(1):154.
5. Zúccaro G, Sosa F. Cerebellopontine angle lesions in children. *Child's Nervous System*. 2007;23(2):177-83.
6. Farid N. Imaging of vestibular schwannoma and other cerebellopontine angle tumors. *Operative Techniques in Otolaryngology-Head and Neck Surgery*. 2014;25(1):87-95.
7. Lak AM, Khan YS. Cerebellopontine angle cancer. *StatPearls [Internet]*; 2021.
8. Bennett M, Haynes DS. Surgical approaches and complications in the

- removal of vestibular schwannomas. Otolaryngologic Clinics of North America. 2007;40(3):589-609.
9. Jagannathan S, Krovvidi H. Anaesthetic considerations for posterior fossa surgery. Continuing Education in Anaesthesia, Critical Care and Pain. 2014;14(5): 202-6.
 10. Laleno DC. Anesthesia of the posterior fossa surgery. Neuroanesthesia and Critical Care (NACC) Course; 2014.
 11. Howell VL, Collins MM, Rochlen LR. Anesthesia for posterior fossa MASS. Neuroanesthesia: A Problem-Based Learning Approach. 2018;9.
 12. Gracia I, Fabregas N. Craniotomy in sitting position: Anesthesiology management. Current Opinion in Anesthesiology. 2014; 27(5):474-83.
 13. Chang B, Raker R, Garc'ia PS. Bispectral index monitoring and intraoperative awareness KEY POINTS; 2019
[Cited 2022 Jan 13]
Available:www.wfsahq.org/resources/anaesthesia-tutorial-of-the-week

© 2021 Prachi et al.; This is an Open Access article distributed under the terms of the Creative Commons Attribution License (<http://creativecommons.org/licenses/by/4.0>), which permits unrestricted use, distribution, and reproduction in any medium, provided the original work is properly cited.

Peer-review history:
The peer review history for this paper can be accessed here:
<https://www.sdiarticle5.com/review-history/80592>